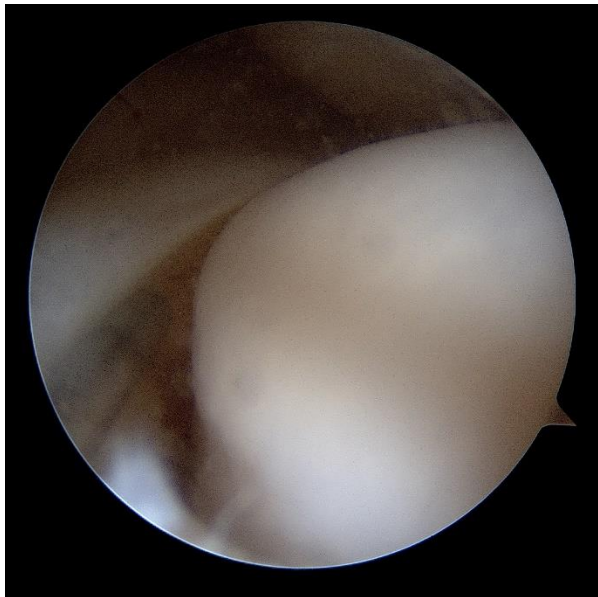




Anterior meniscus root tear ?

Burt Klos
Stephan Konijnenberg
Netherlands



Anterior root tear ?

- Anterior meniscus dislocation 1984 1998
 - Anterior meniscus subluxation 2003
 - Hypermobility snapping medial meniscus 2008
 - Detached anterior horn medial meniscus 2015
 - Anterior medial root tear repair 2015/2016
 - Anterior meniscus extrusion 2018
-
- **Anteromedial Menisocofemoral Ligament of the Anterior Horn of the Medial Meniscus: Clinical, Magnetic Resonance Imaging, and Arthroscopic Features. Arthroscopy 2018**
 - **Incidence : 0,5 %**
 - **MRI negative**
 - **Arthroscopy : Band and extrusion**


[Am J Sports Med.](#) 1984 Jan-Feb;12(1):57-64.

Symptomatic dislocation of the anterior horn of the medial meniscus.

[Clancy WG](#), [Keene JS](#), [Goletz TH](#).

13 patients

The first four patients had traditional medial meniscectomies, the next four patients had repair of the anterior horn, and the last five patients had partial resection of the meniscus

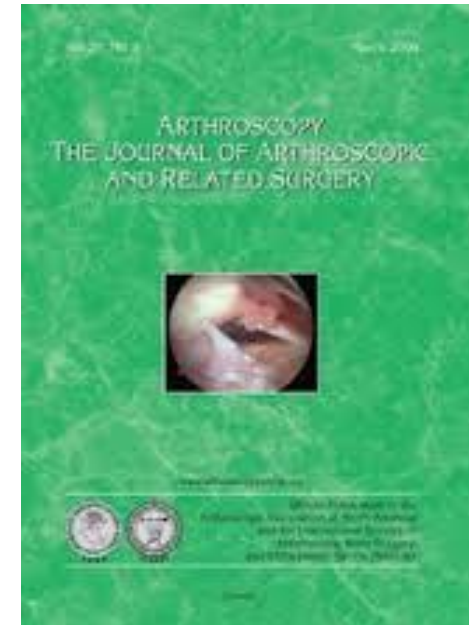


[Arthroscopy](#). 1998 Apr;14(3):246-9.

Dislocating anterior horn of the medial meniscus.

[Pinar H¹](#), [Akseki D](#), [Bozkurt M](#), [Karaođlan O](#).

- Dislocating anterior horn of the medial meniscus is a normal anatomic variant with little or no clinical significance



[J Radiol.](#) 2008 Jan;89:53-6.

[Hypermobile snapping medial meniscus: features on flexion-extension MRI].

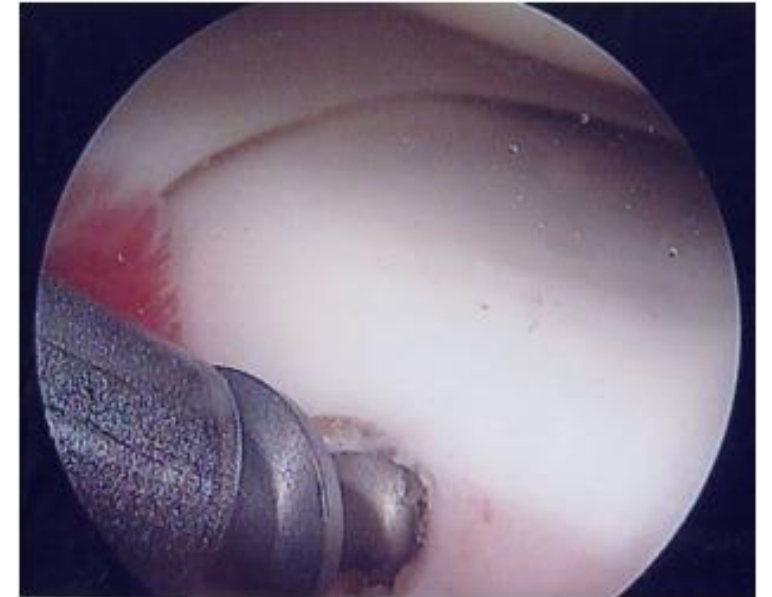
[Poey C¹](#), [Couette P](#), [Savorit L](#), [Guy F](#), [Raynaud M](#), [Dutheil A](#).

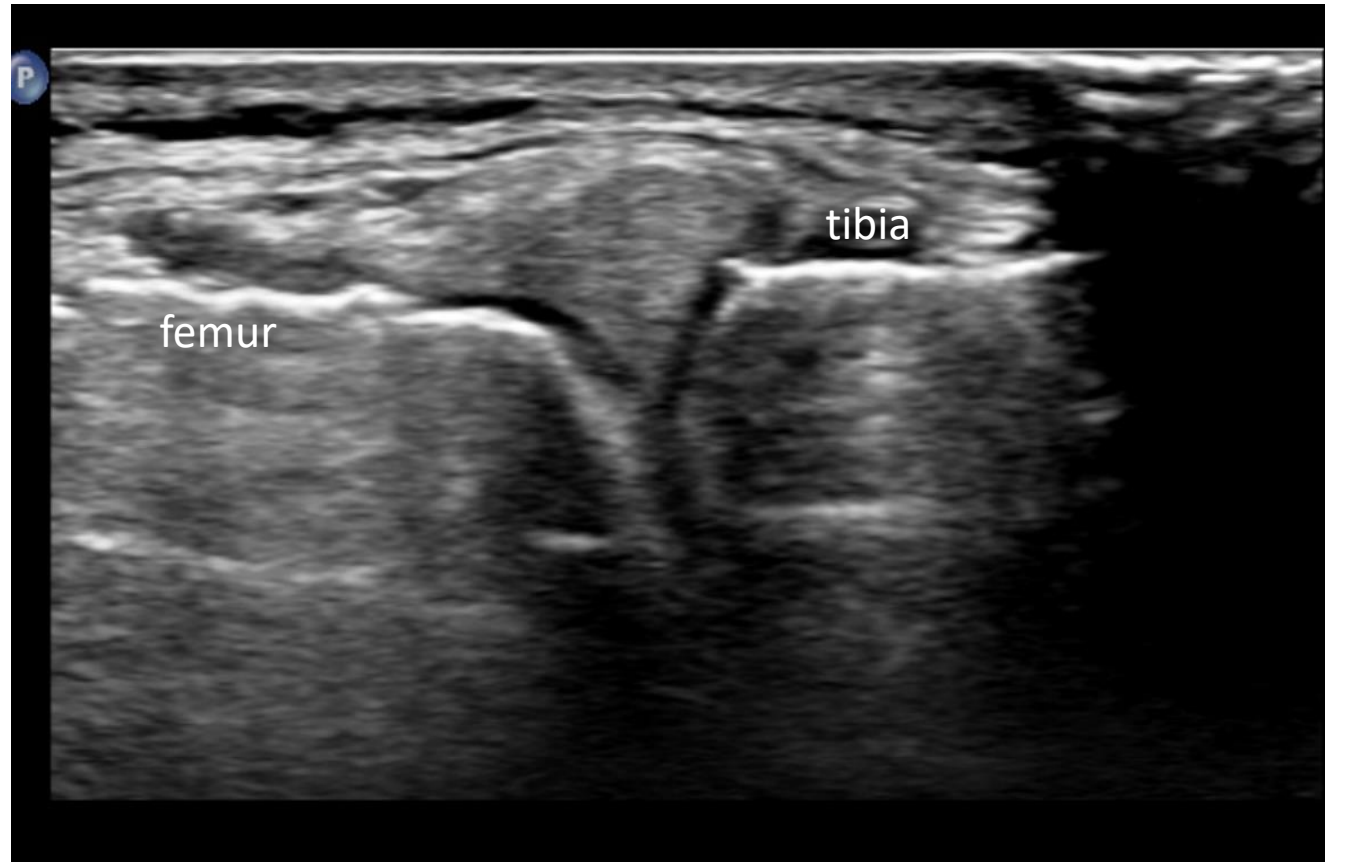
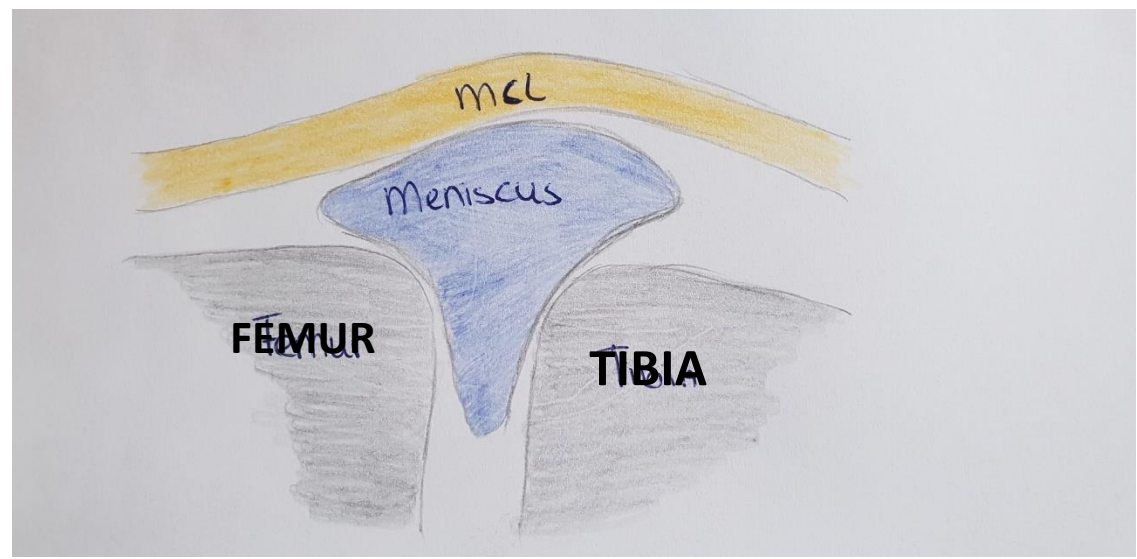
- The anterior horn of the medial meniscus was anteriorly subluxed during extension with reduction during flexion.



Anterior medial root meniscus repair

- Menge ,La Prade
- Anterior meniscus root repair , Arthroscopy Techniques 2016
- Double tunnel pull out , cortical fixation device
- Osti , Maffuli , Translational medicine 2015
- Anterior meniscus root tear all inside repair
- Shoulder suture screw anchor . N = 12

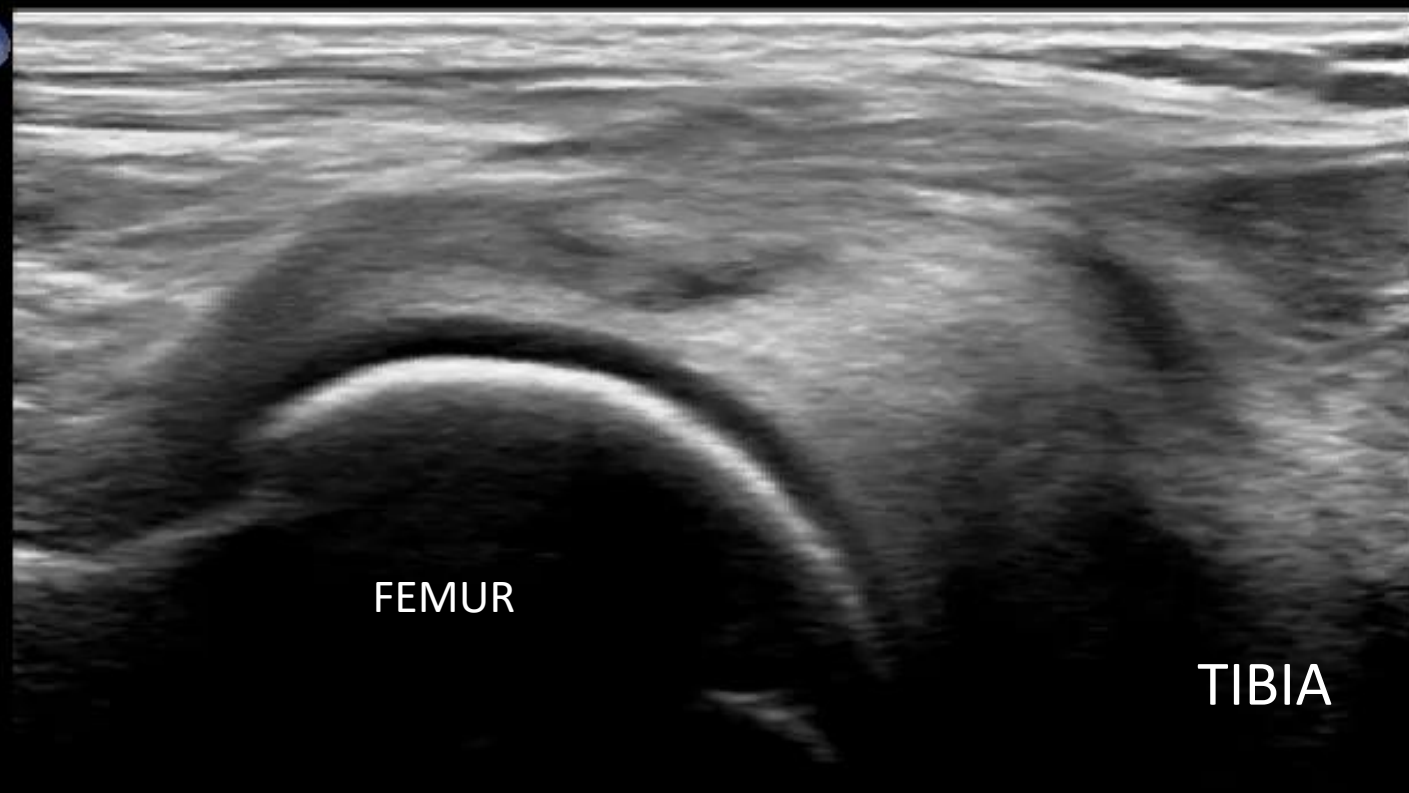




260200VE
415015P0101001
MSR Gen
2/26/2000 F
10/12/04
4:08 PM
Image 1/181
RS

2D
64%
Dyn R 68
P Med
Gen

P



FEMUR

TIBIA

TIS0.4 SEM KONIJNENBERG
MI 0.7 Zoom 100%

M3

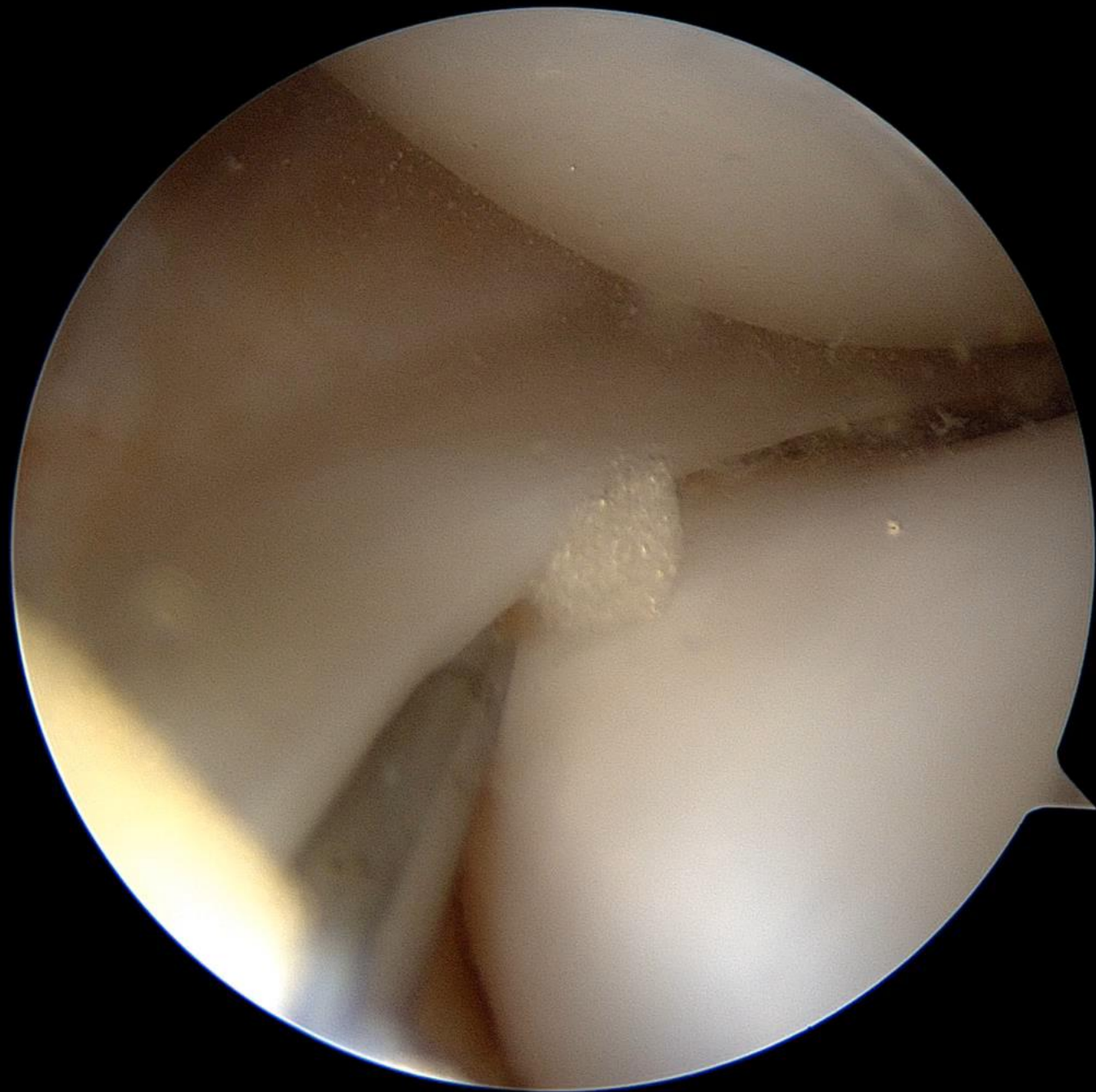

4.0cm

bpm

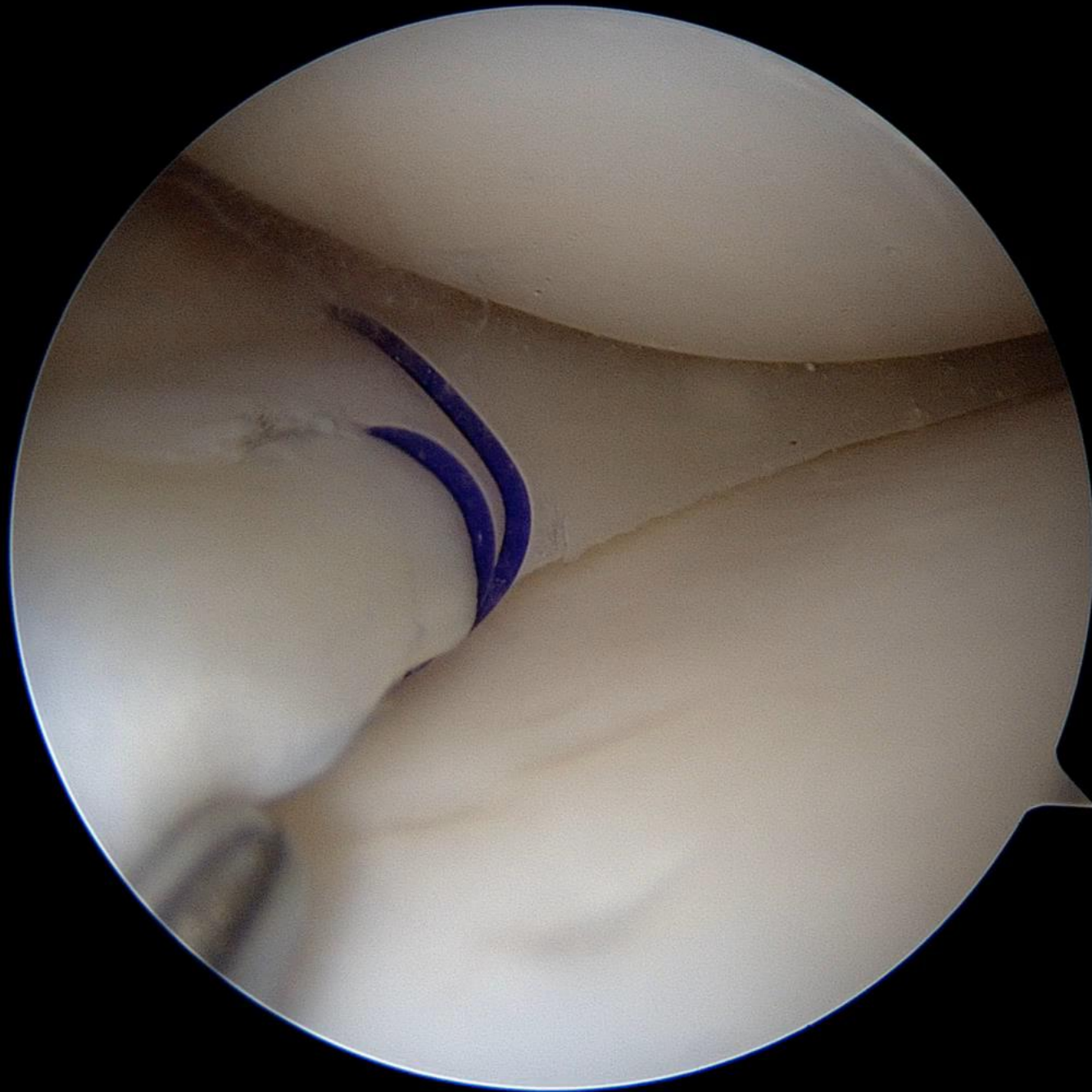
Knee LeftMedial Post

0 BPM

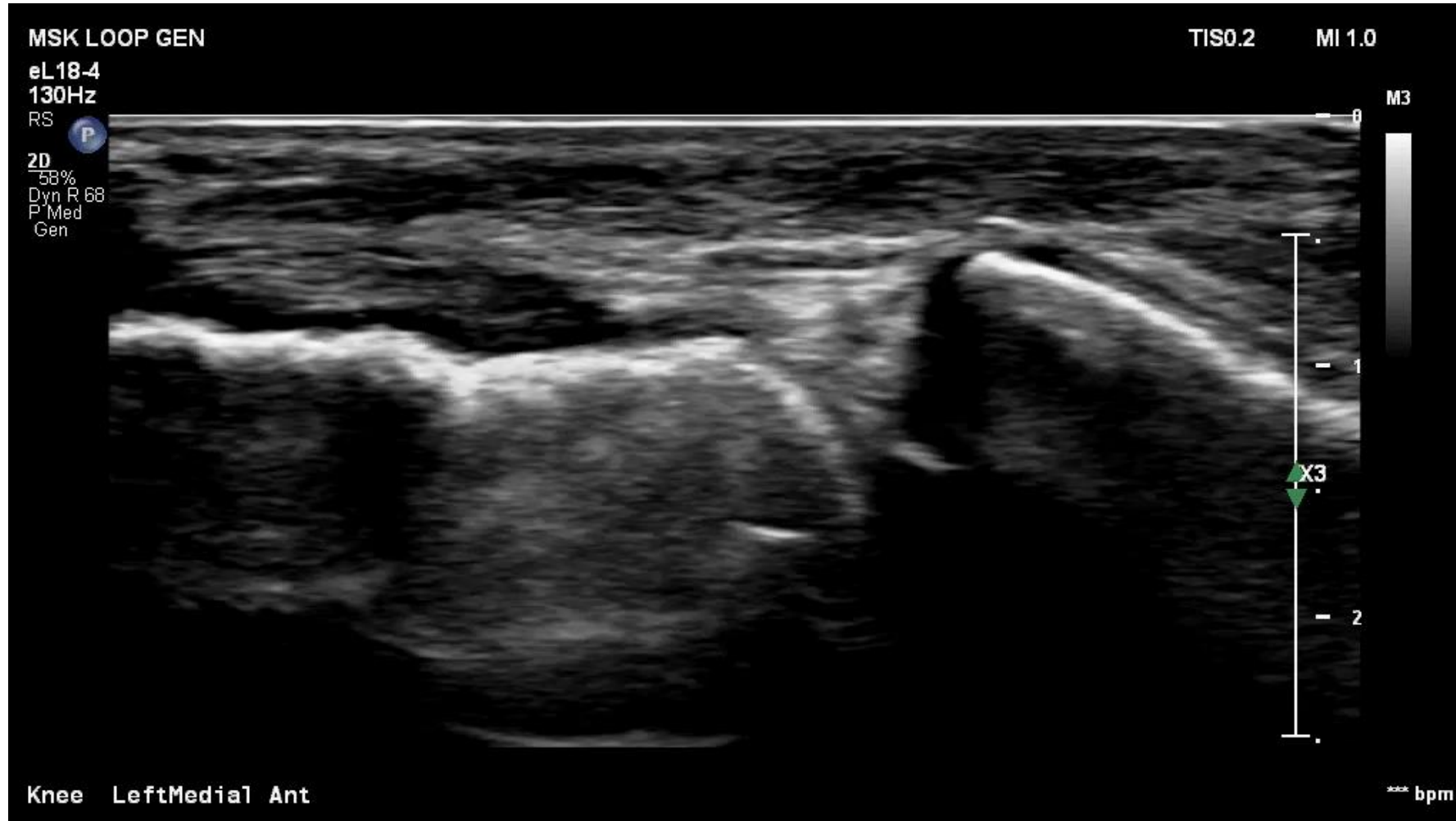


repair

- Video
- Probe
- Suture
- Repair



Ultrasound 6 wk after meniscus anterior repair



Conclusion

- Meniscus anterior instability
- Dynamic imaging > expected higher incidence
- Meniscus extrusion reduced with meniscus sutures ?
- No numbers , no follow up

