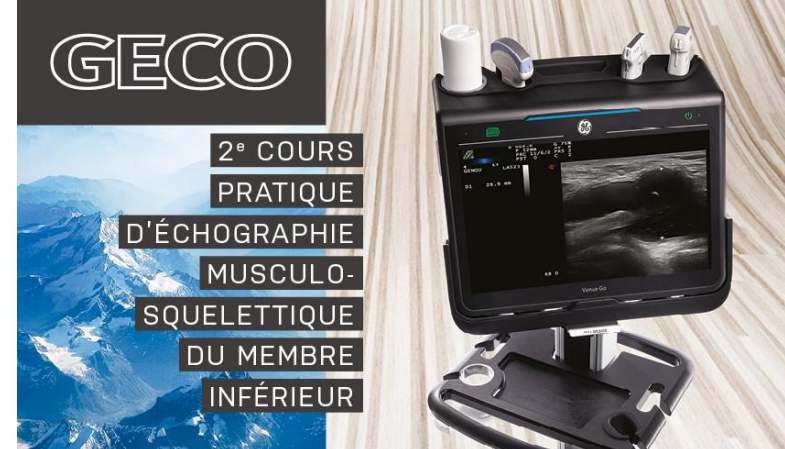



Burt Klos MD PhD
Stephan Konijnenberg MD

**ALL lesions diagnosis with
ultrasound**

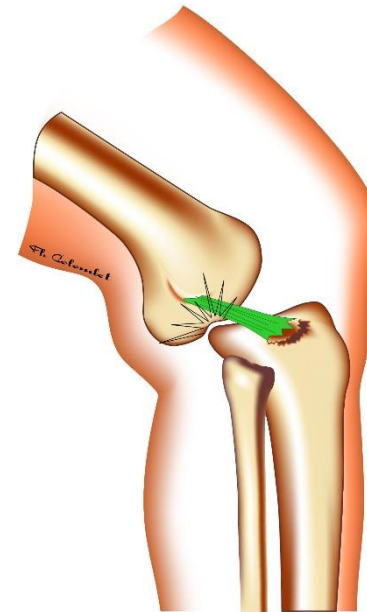


Anterolateral Ligament Complex Lesions in ACL Combined Injuries

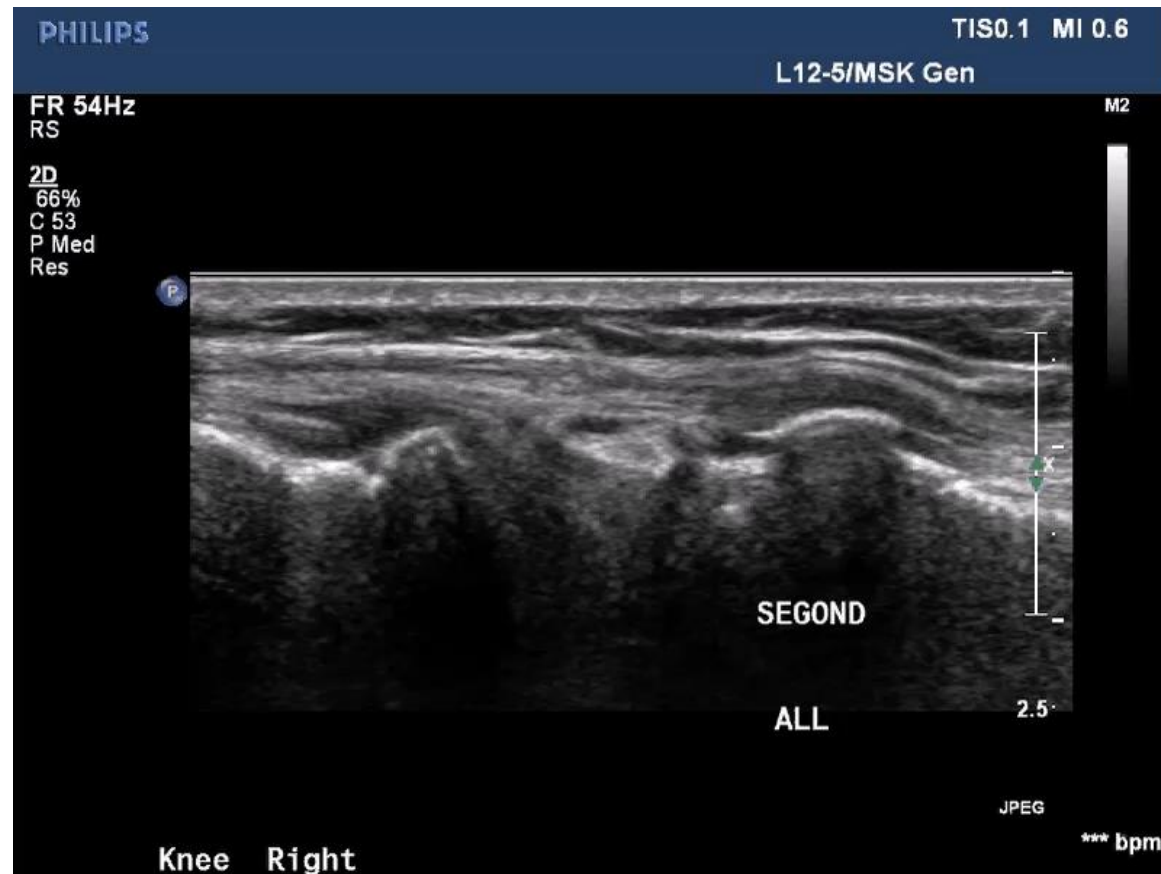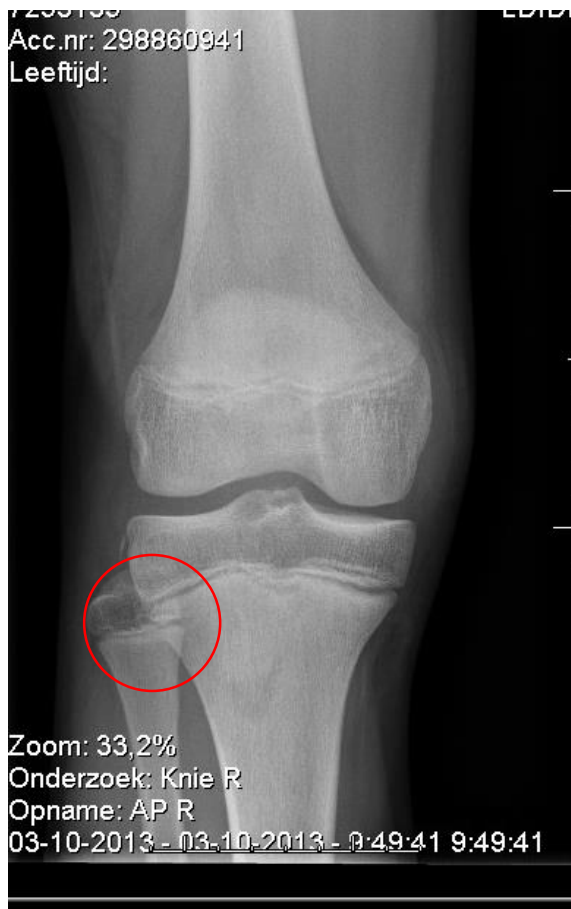Burt Klos

Stephan Konijnenberg

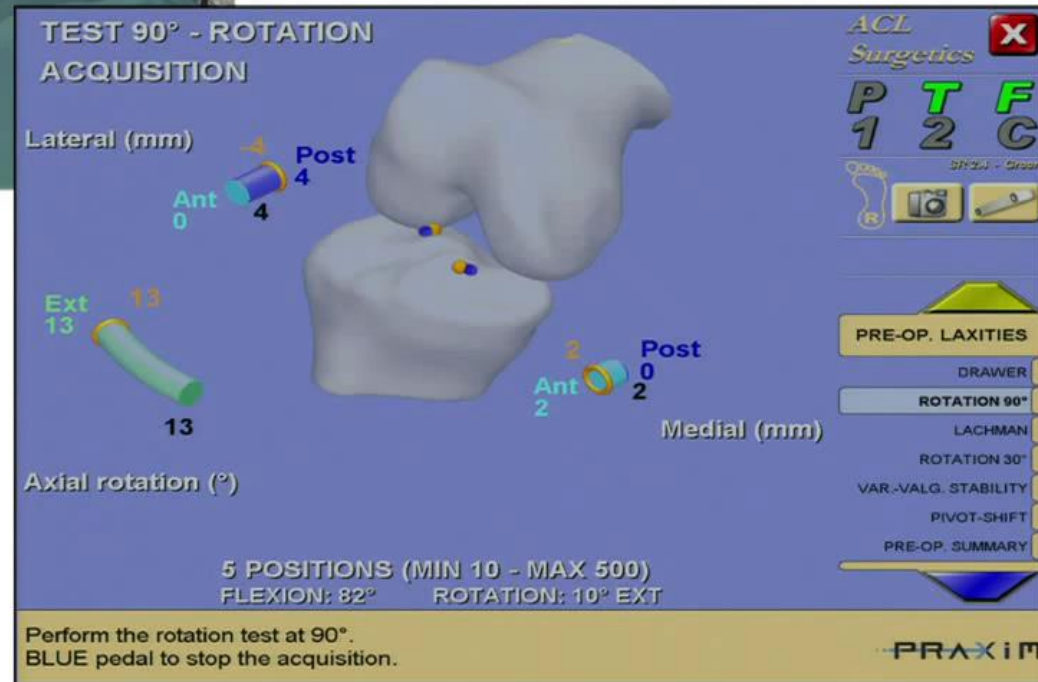
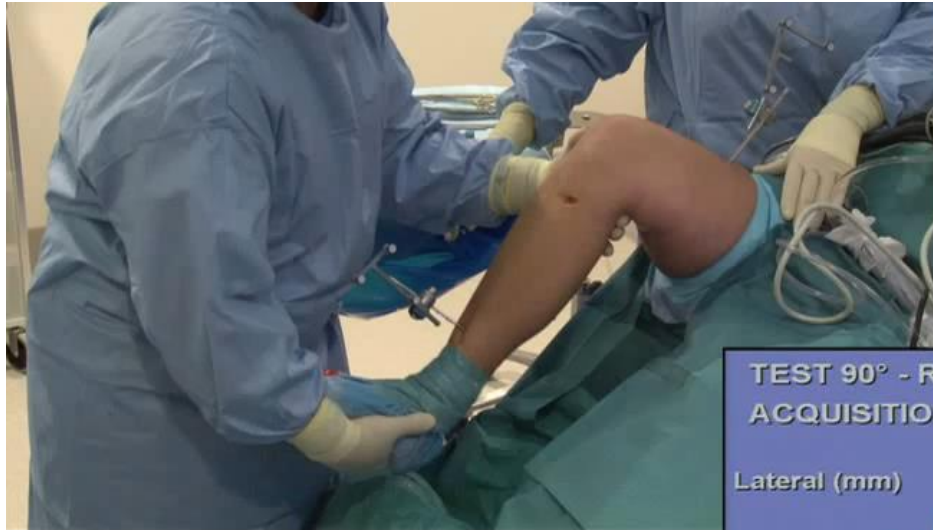The Netherlands



Segond fractuur

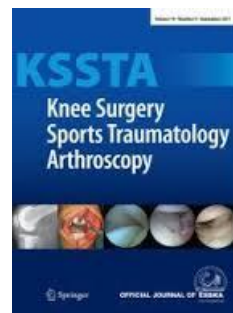


Rotation



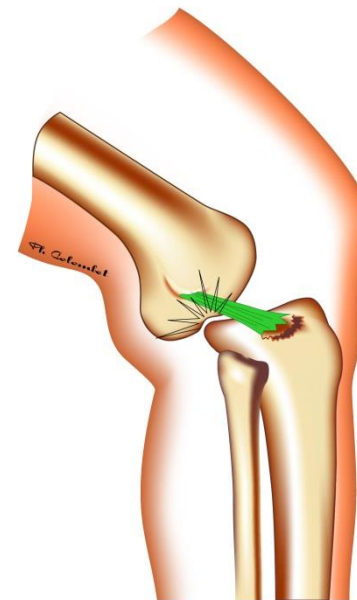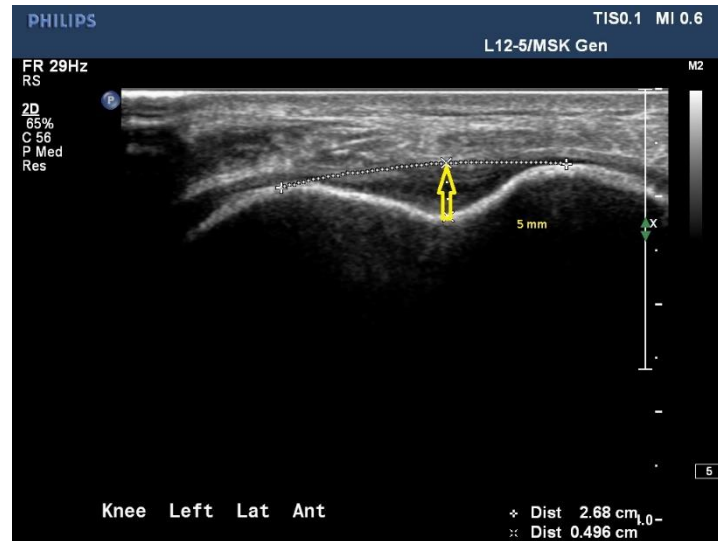
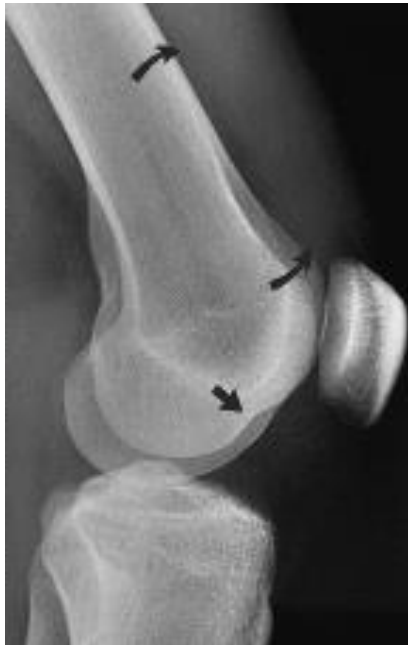KSSTA April 2017

- High prevalence of ALL complex Segond avulsion using ultrasound imaging .
- Klos / Scholtes / Konijnenberg
- Ultrasound should be considered in case of impaction fracture to check for Segond avulsion.



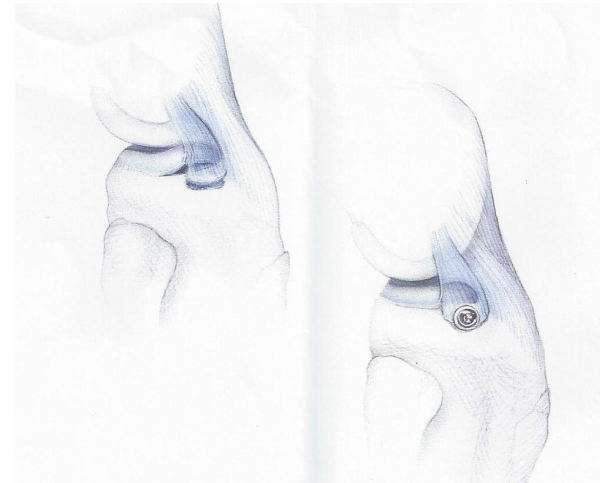
Ultrasound imaging

- 88 patients with ACL #
- 25 Segond lesions (29 %)
- 40 Impaction # lateral FC (46%)

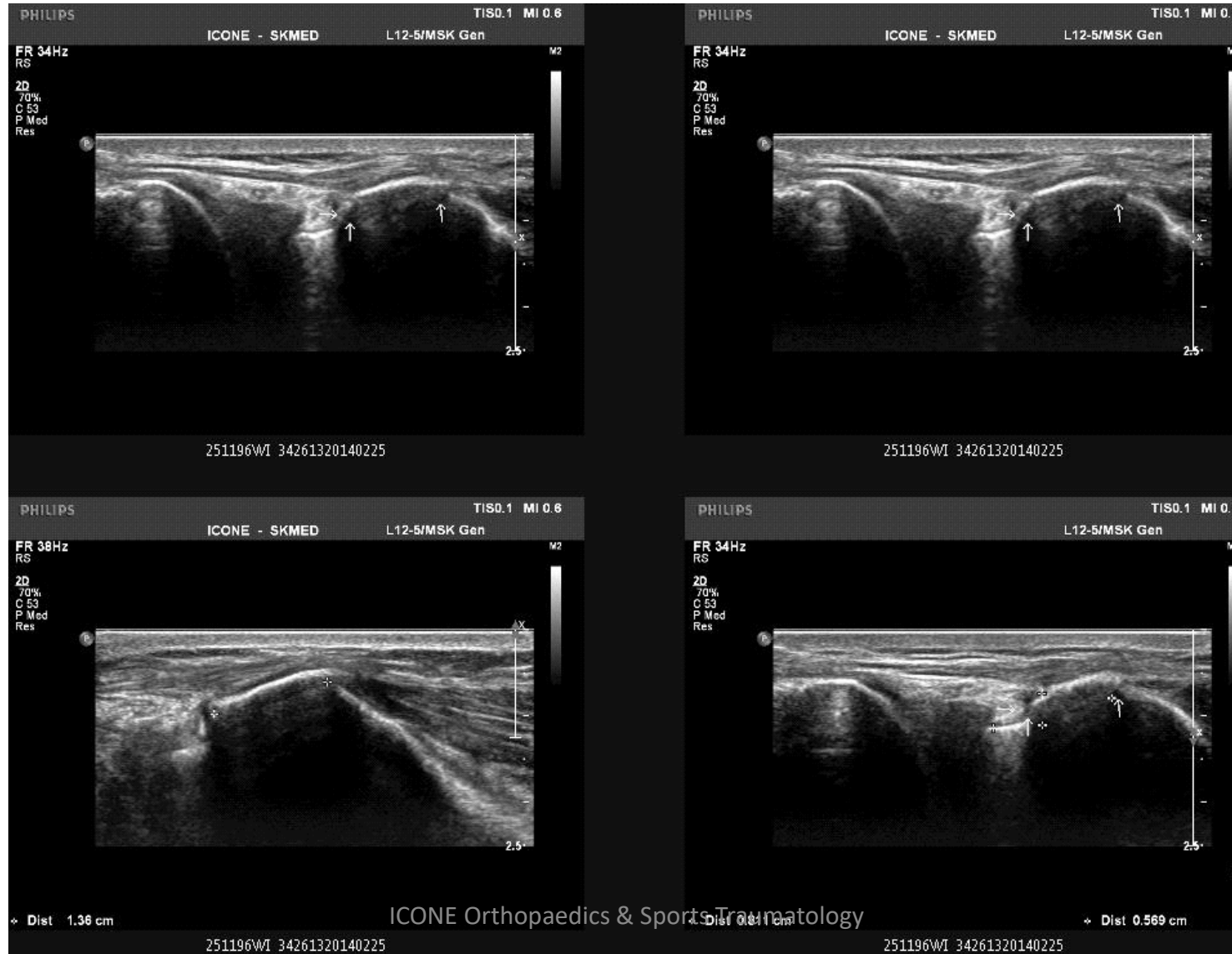


Imaging Second avulsion

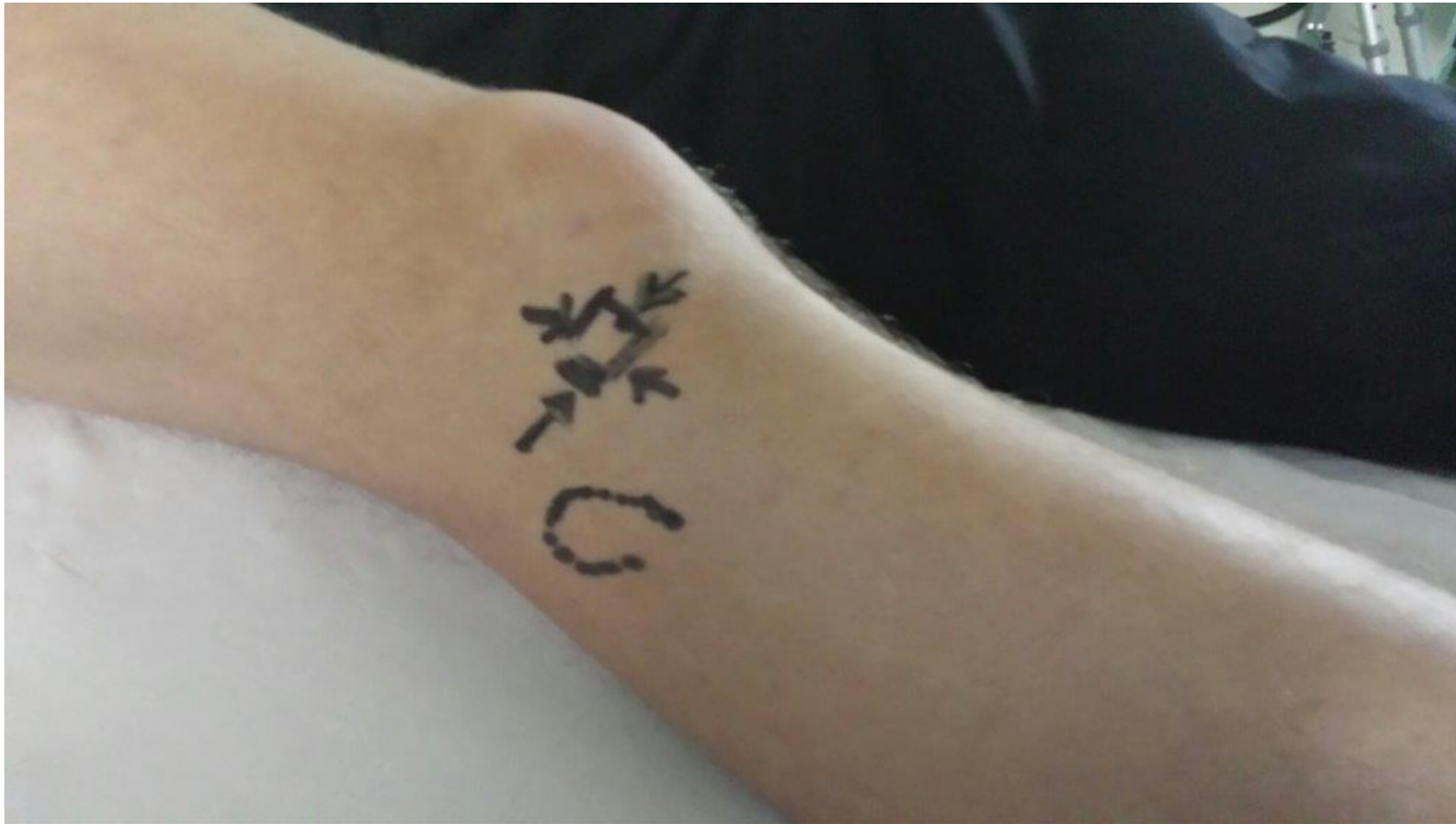- Incidence in MRI 3 % Resnick USA
- Incidence in X ray CORR Hess D 9 %
- Incidence ultrasound 29 % (ICONE)
- Higher velocity trauma ?
- Refixation / Feagin :



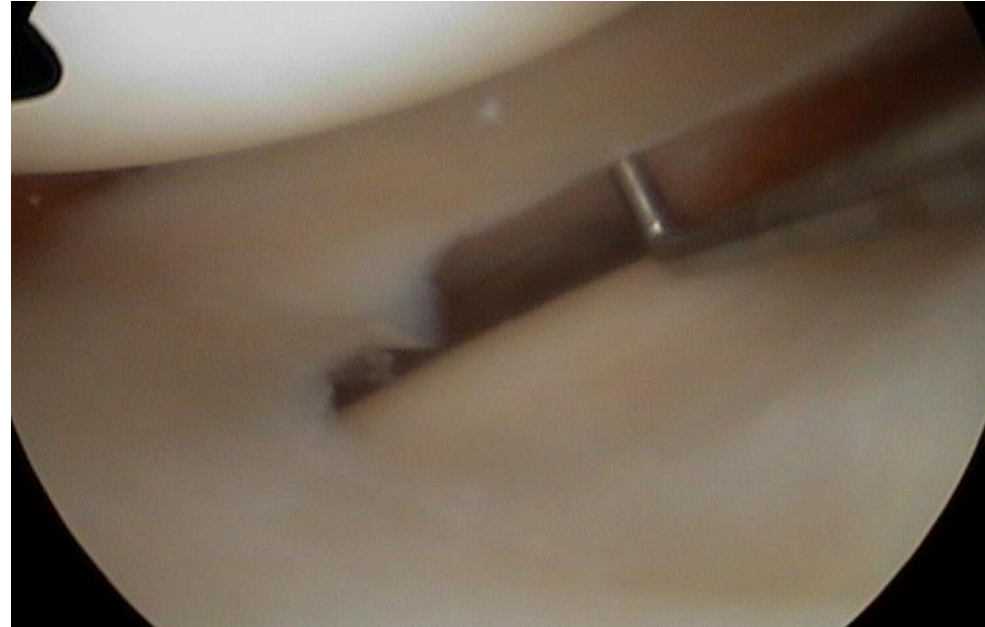US patho anatomy ALL complex



Preoperative marker of Segond avulsion / ultrasound

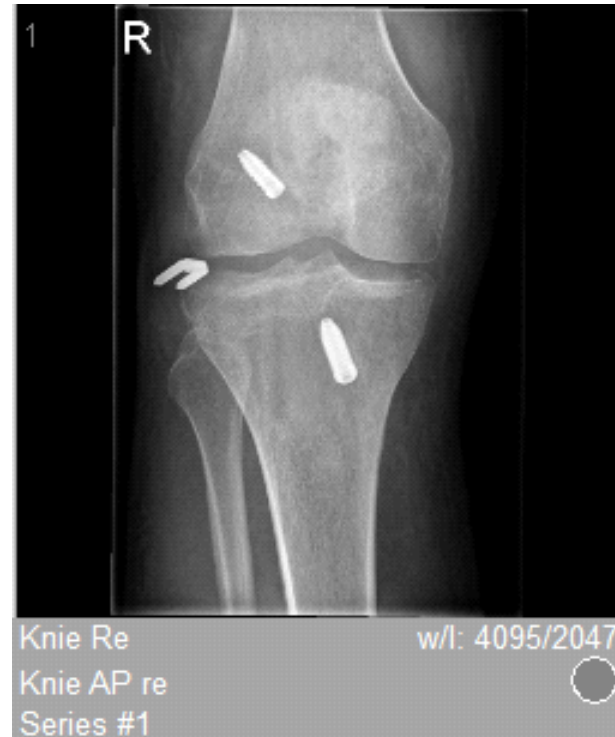
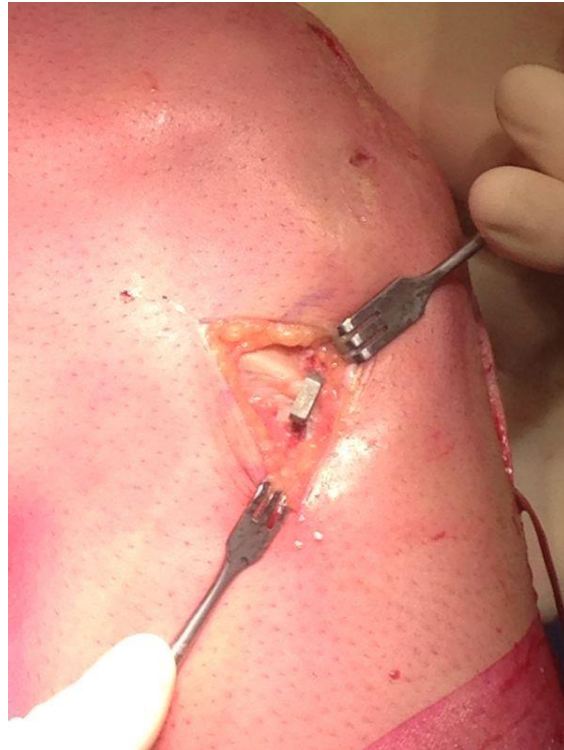
Peroperative imaging lift off lateral meniscus

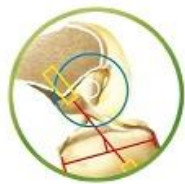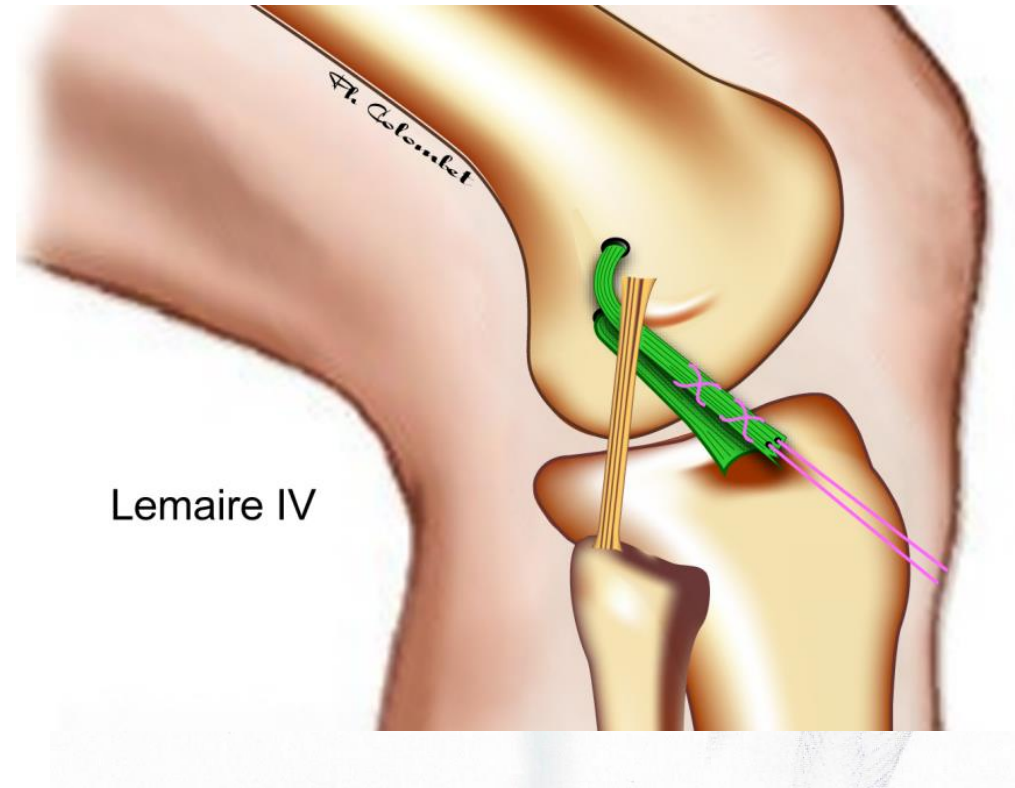

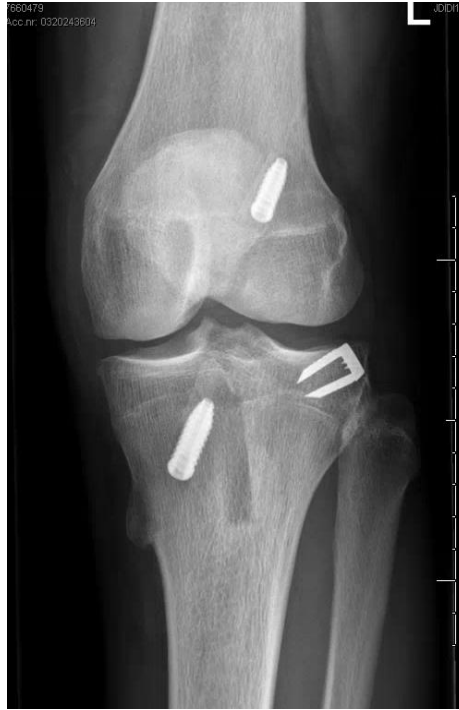
Case Report : Refixing ALL / second #

Checking the pivot on the table is pulling the staple off / prove of importance in stability ?



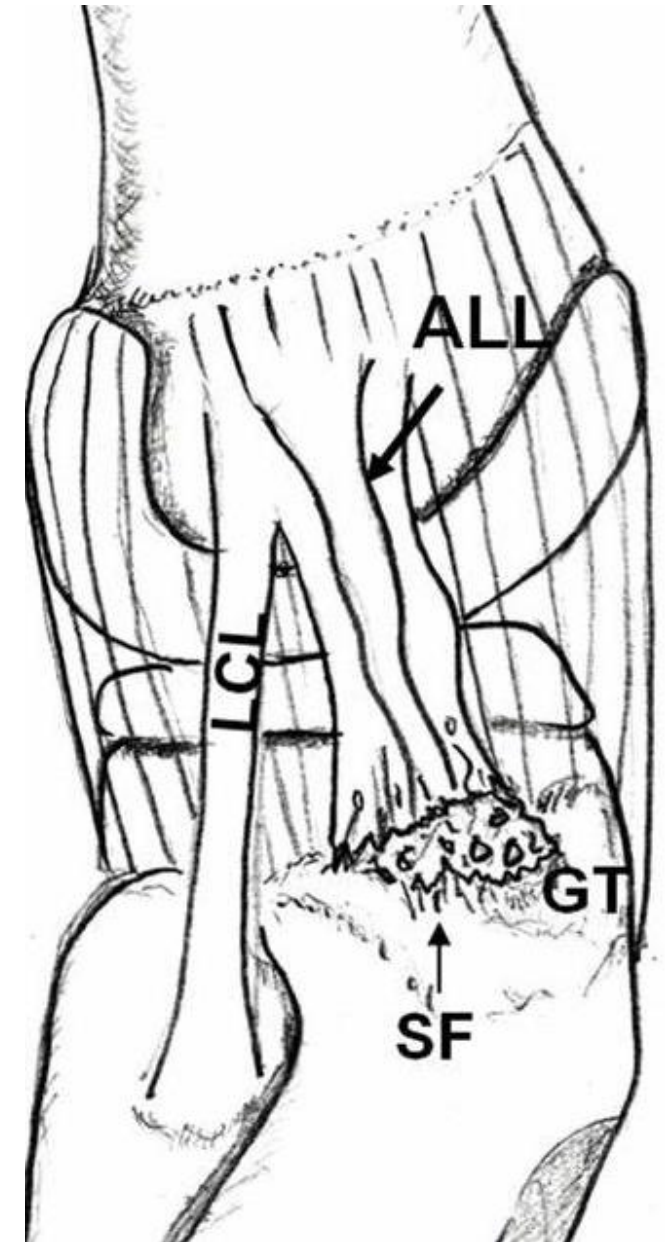
Refixing Segond or reconstruction AL tenodesis?



ICONE

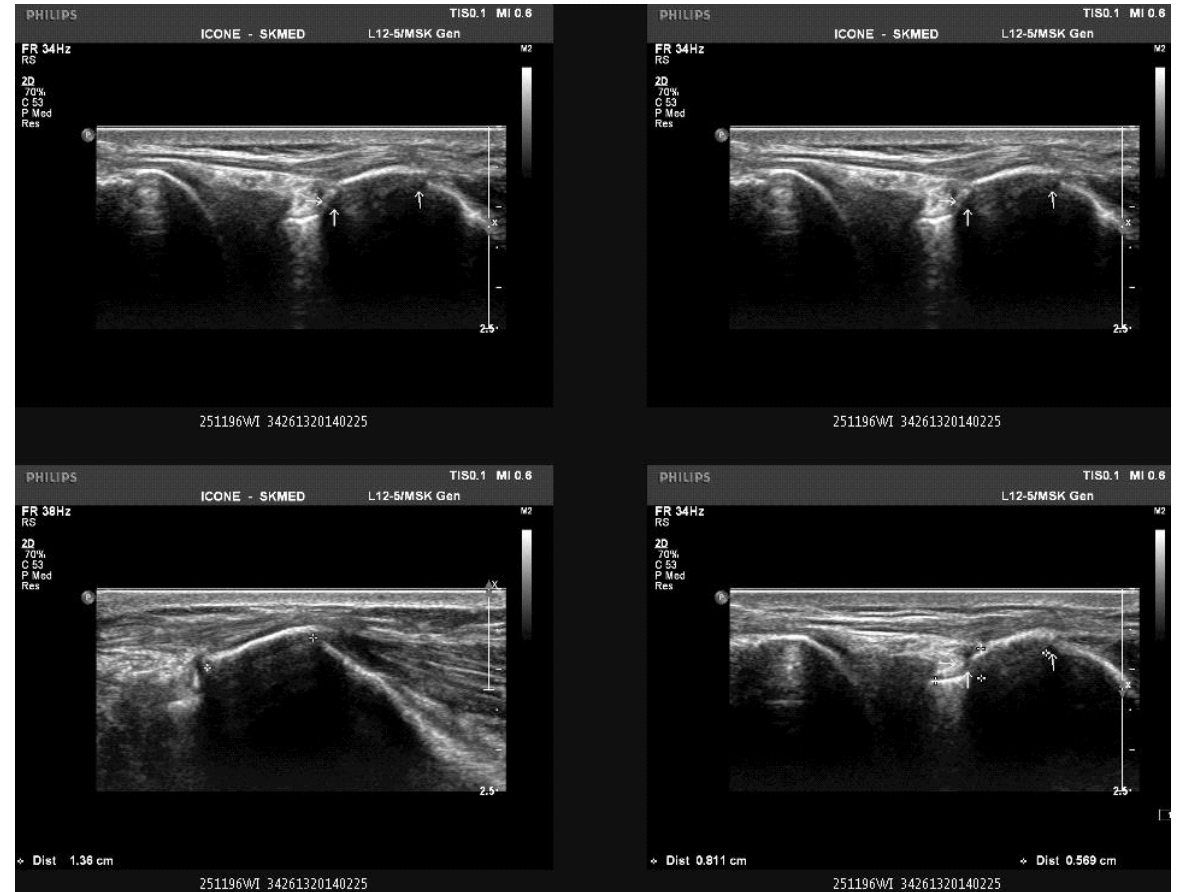
Discussion ALL lesions

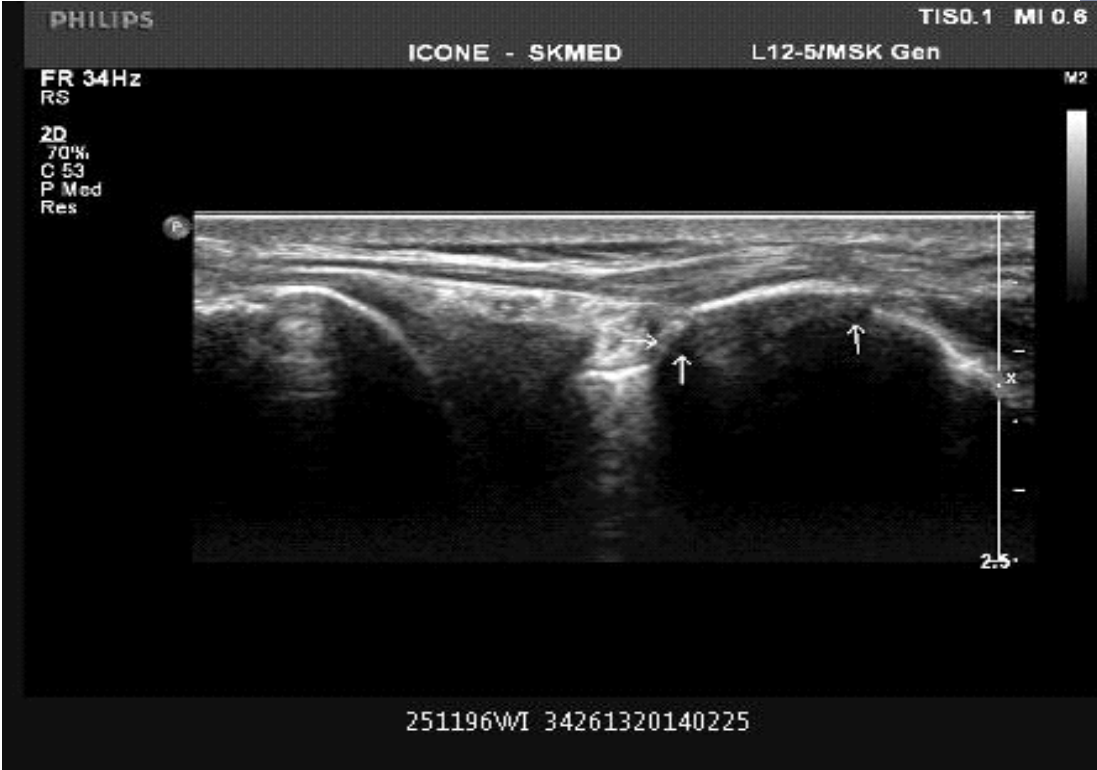- Ferretti I : surgical dissection in ACLR :
 - Arthroscopy 2016 ALL 54/60 lesions
 - Distal lesions 19/60 (32 %)
- Cavaignac F
 - Arthroscopy 2017 :
 - Ultrasound Segond avulsion 15/ 30 (50 %) /
 - MRI 4/30 (13 %)



Discussion Anatomy

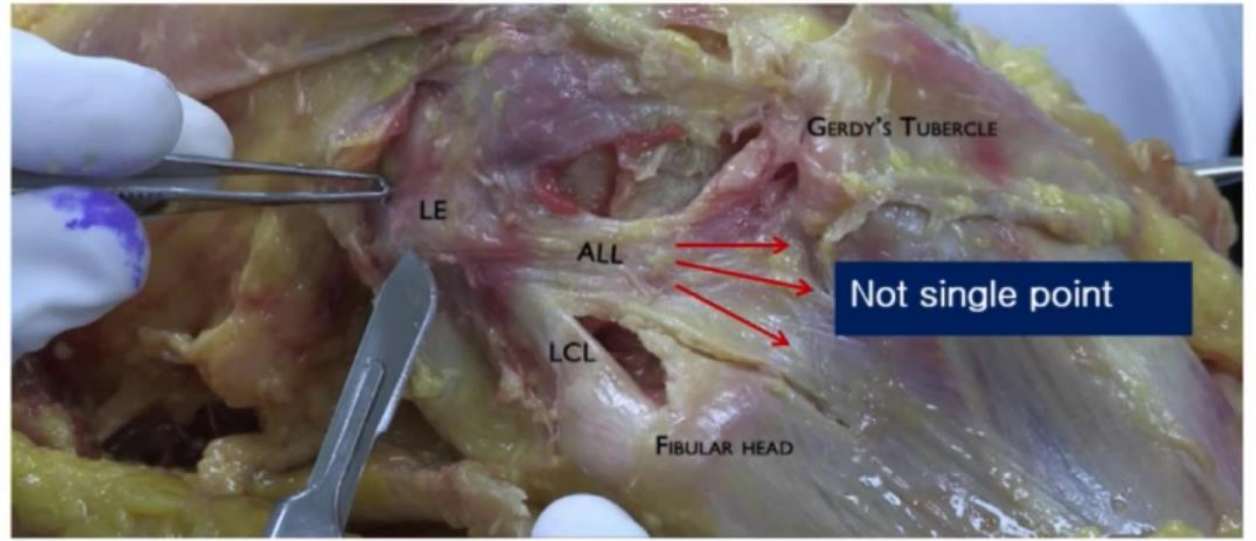
- Segond avulsion >
 - anatomy and MRI >
 - ITB and AL capsule avulsion
 - Campos Resnick Radiology 2001
- Segond avulsion >
 - 36 Segond # MRI ALL complex avulsion
 - Skaikh Fu AJSM 2017
- Segond avulsion >
 - Case report Segond # Ultrasound
 - Combined ITB and AL capsule attachment
 - Albers Fu KSSTA April 2017





Surgical Dissection of the Anterolateral Ligament

Matthew Daggett, D.O., M.B.A., Kyle Busch, B.S., M.S., and Bertrand Sonnery-Cottet, M.D.



EDPEDIA ORTHOSCOPE
 Our early indication for ALL
 Full text report
 Published by the journal Orthopedics
 Please contact us
 For more information visit our website

3:53:26

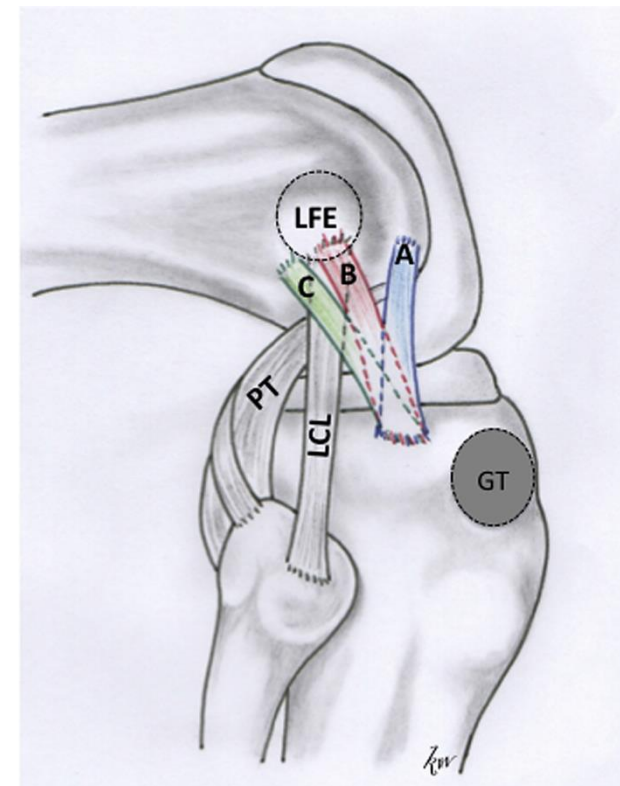
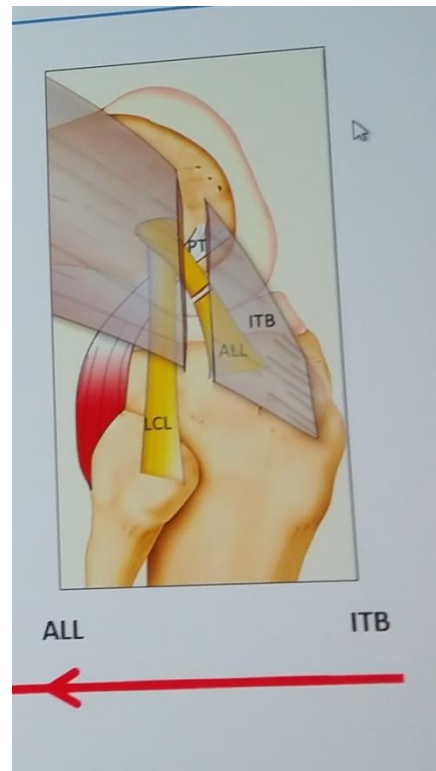
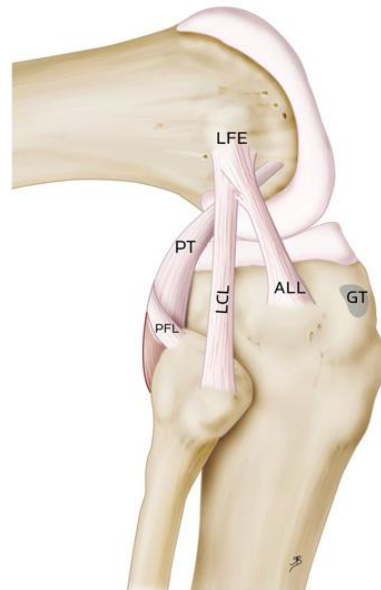
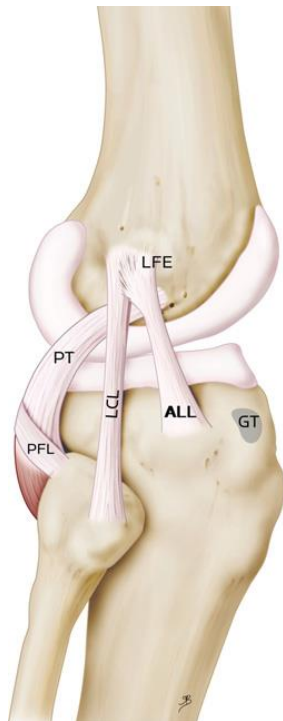
be clearly identified **as a distinct structure** with an attachment near lateral epicondyle (Prox. & Post.) and an **insertion in a fan-like fashion** on the tibia

ALL anatomy 2016

Belgium

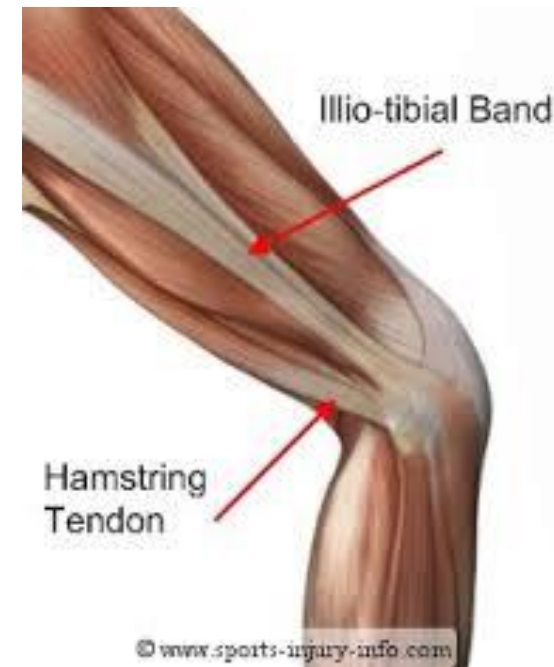Lyon

Toulouse

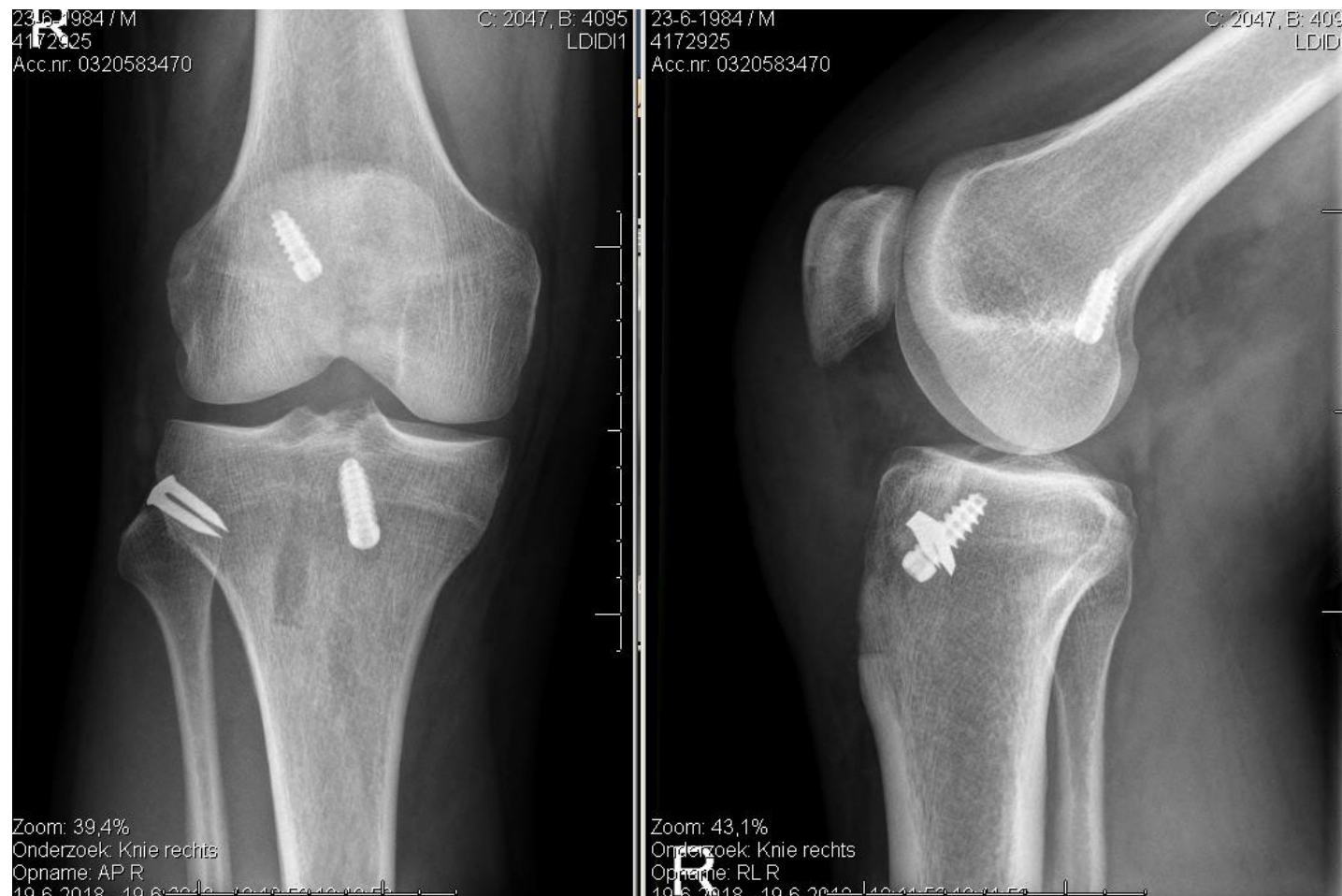


Kittl /Weiler /Williams /Amis

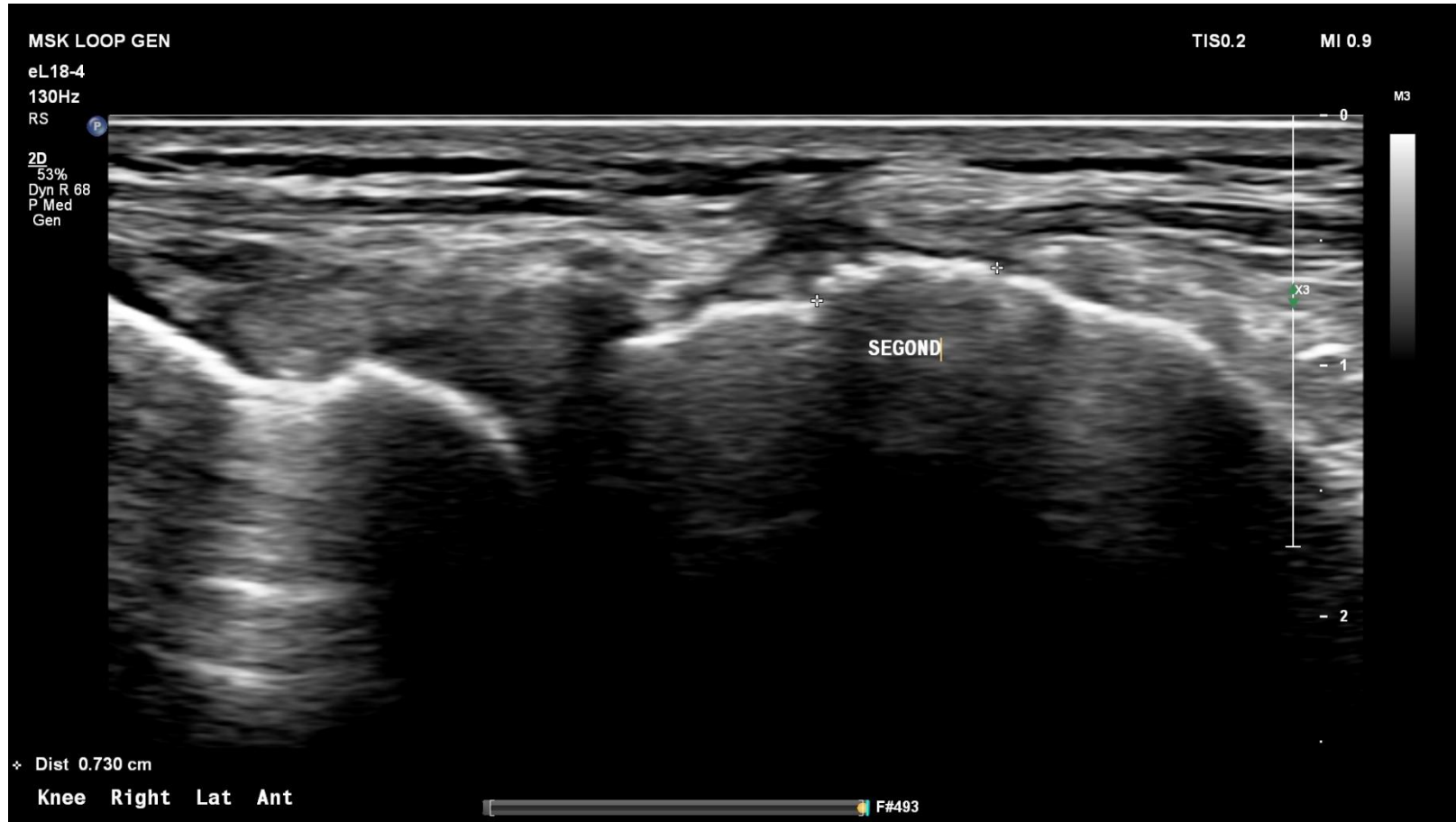
- Am J of Sport Medicine 2016
- Restraints to AL instability
- ITT superficial 56 % resistance IR
- ITT deep 30 % resistance IR
- ALL 4 %
- ACL 10 %



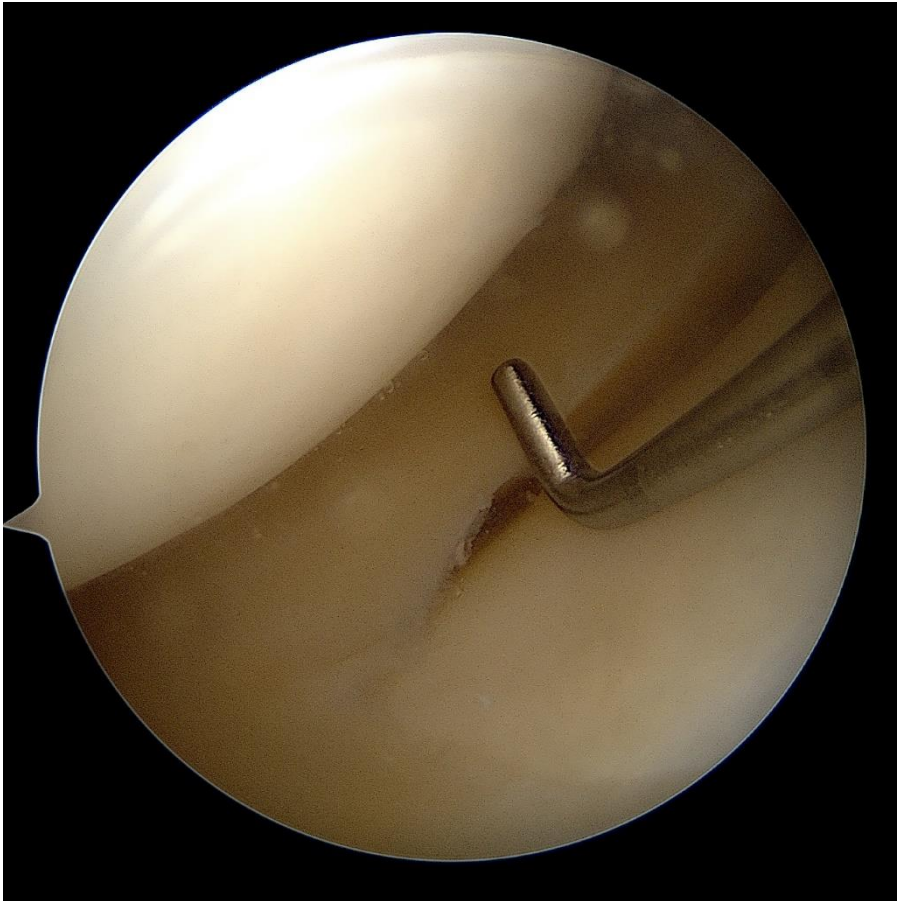

Refixation Segond fracture

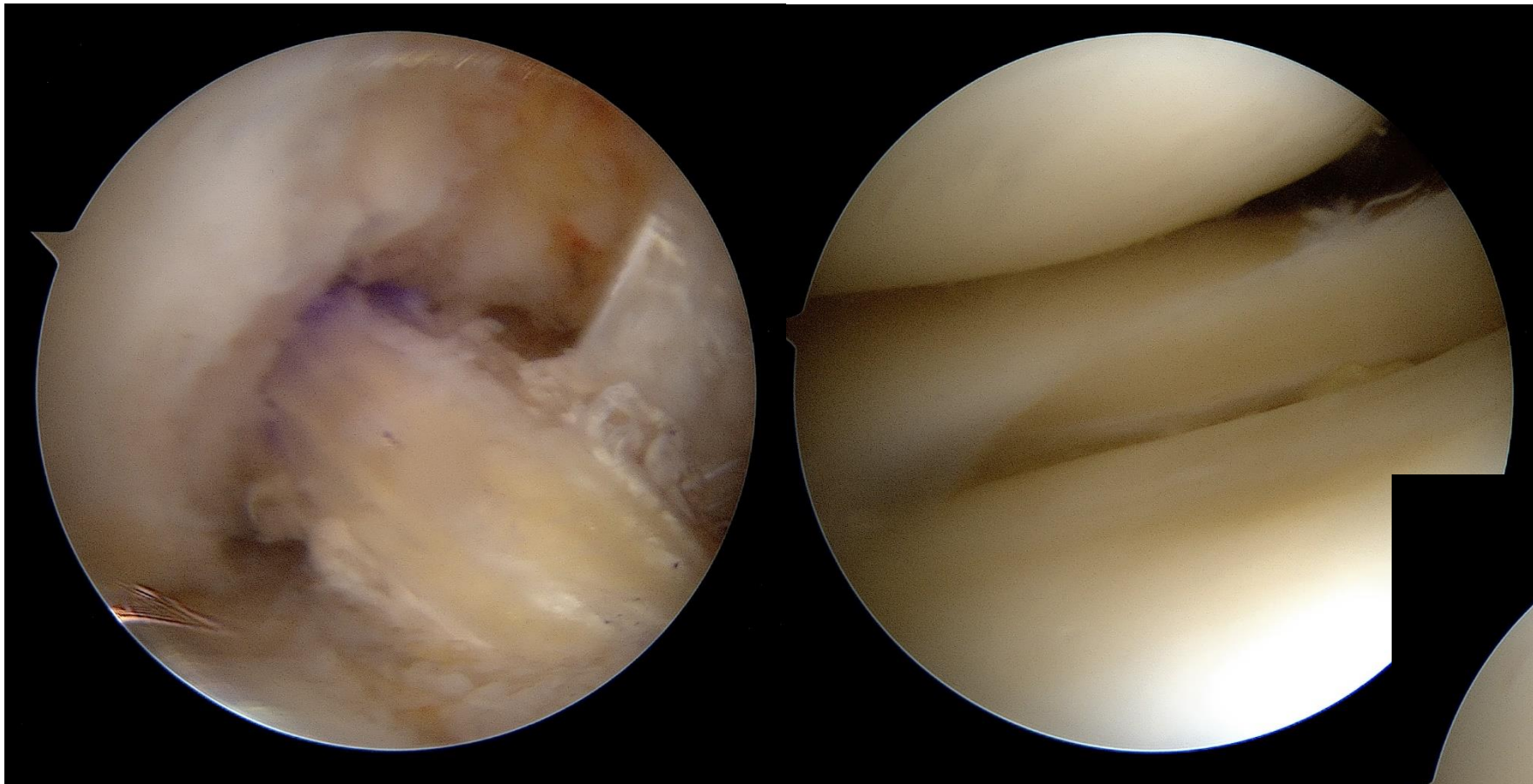


Segond fracture avulsion (consolidated malunion)

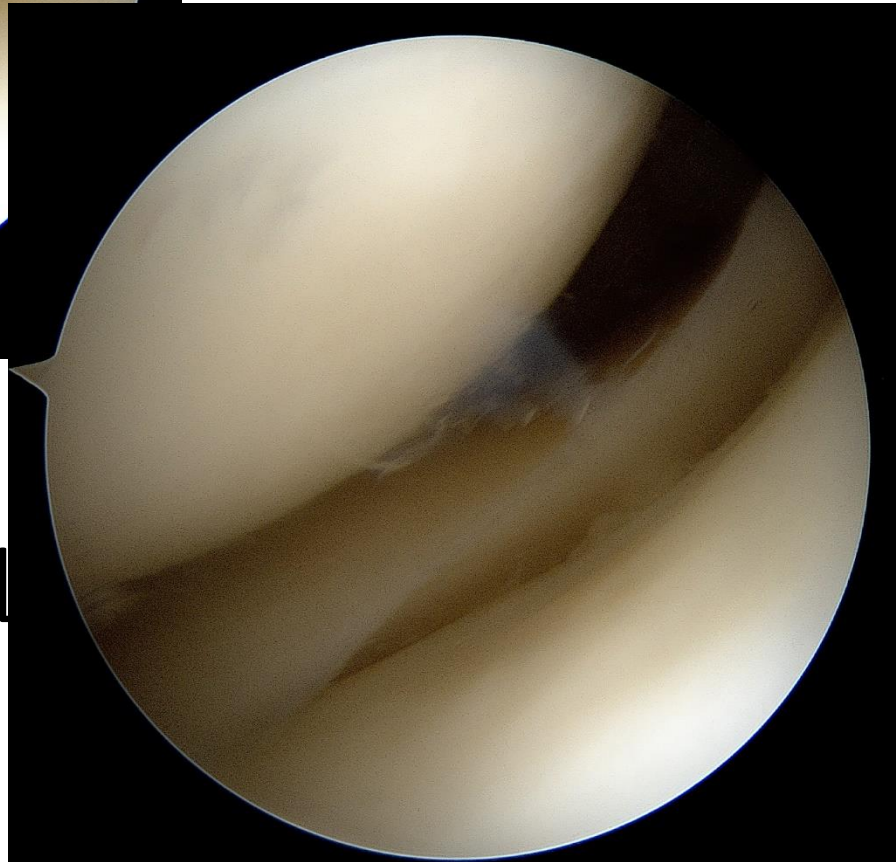


Arthroscopic evaluation

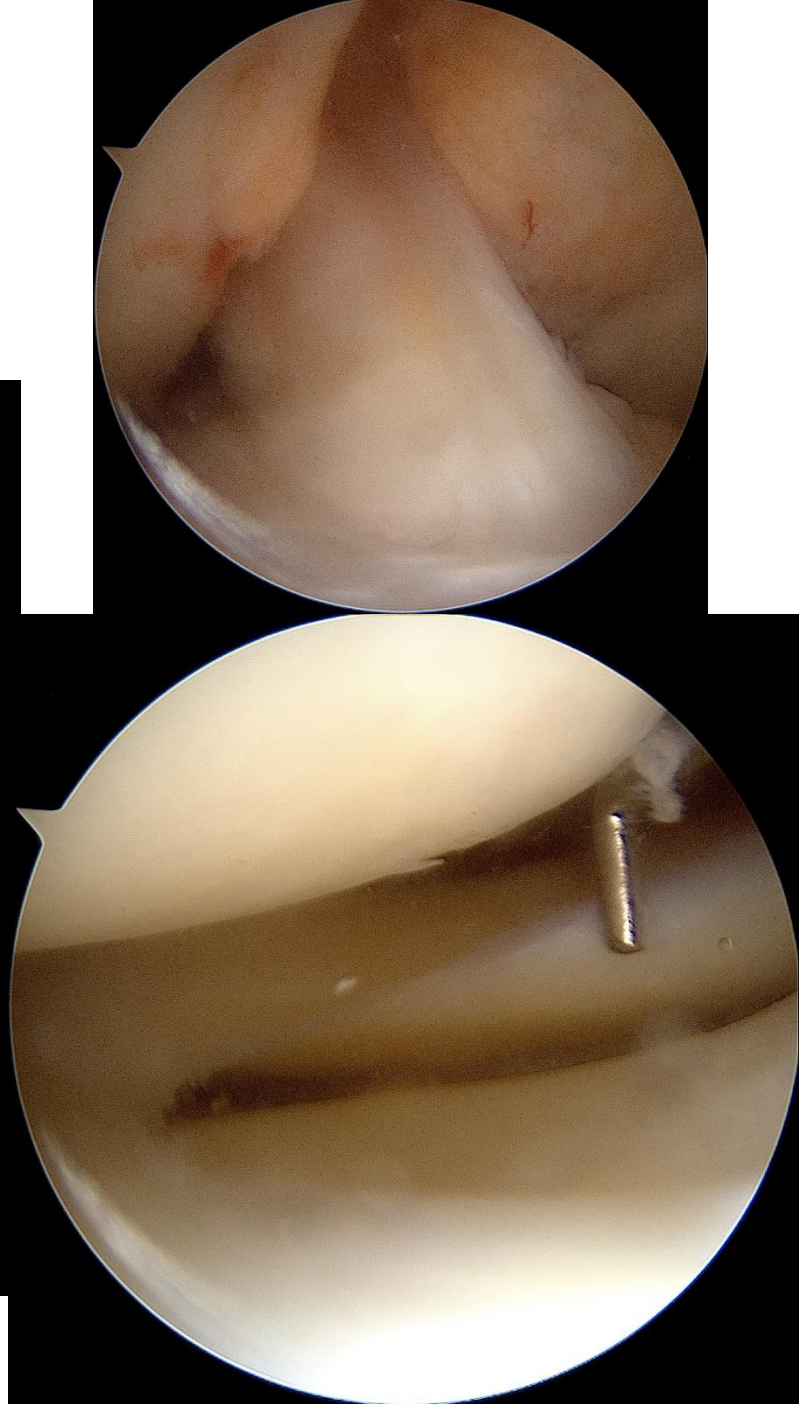
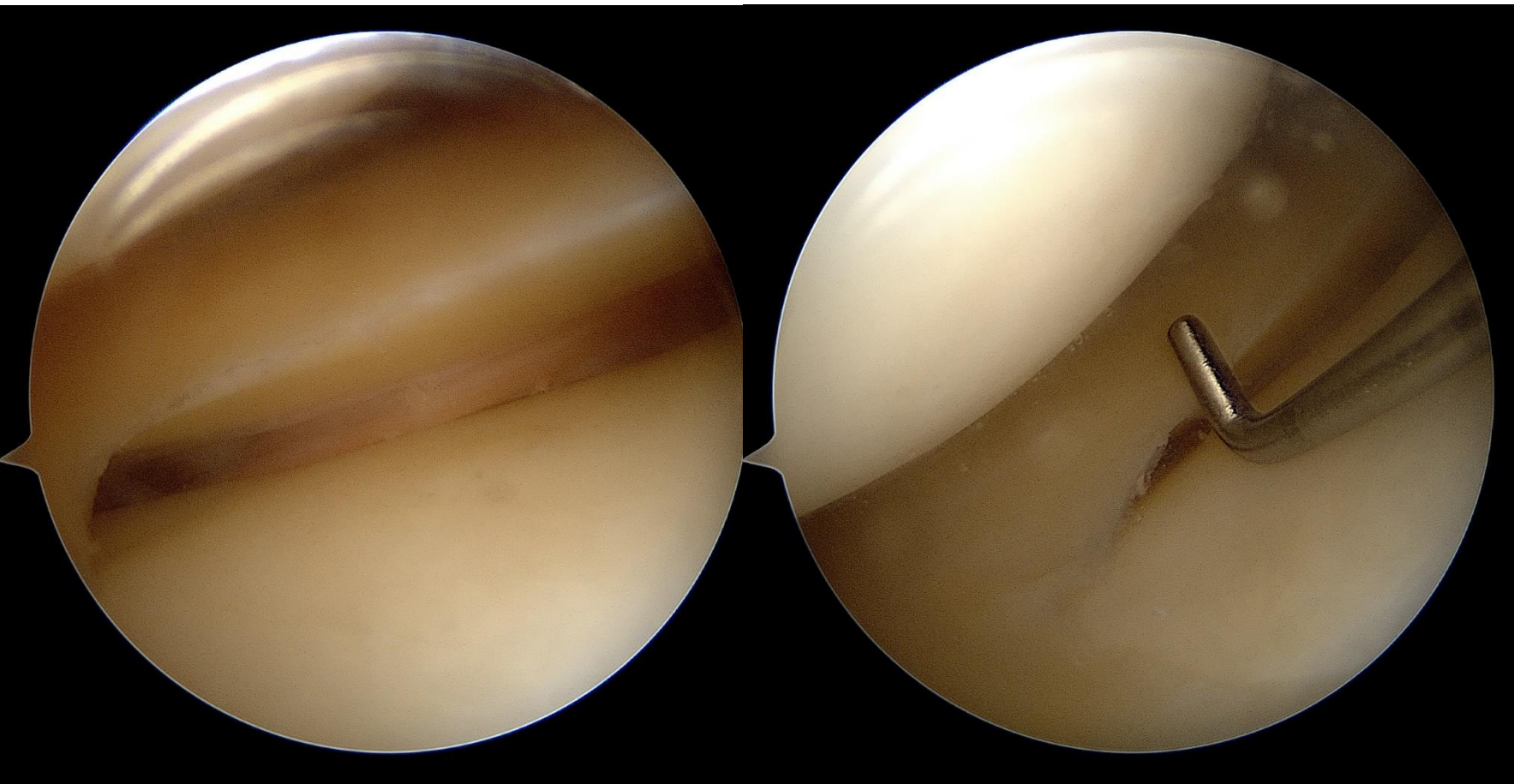




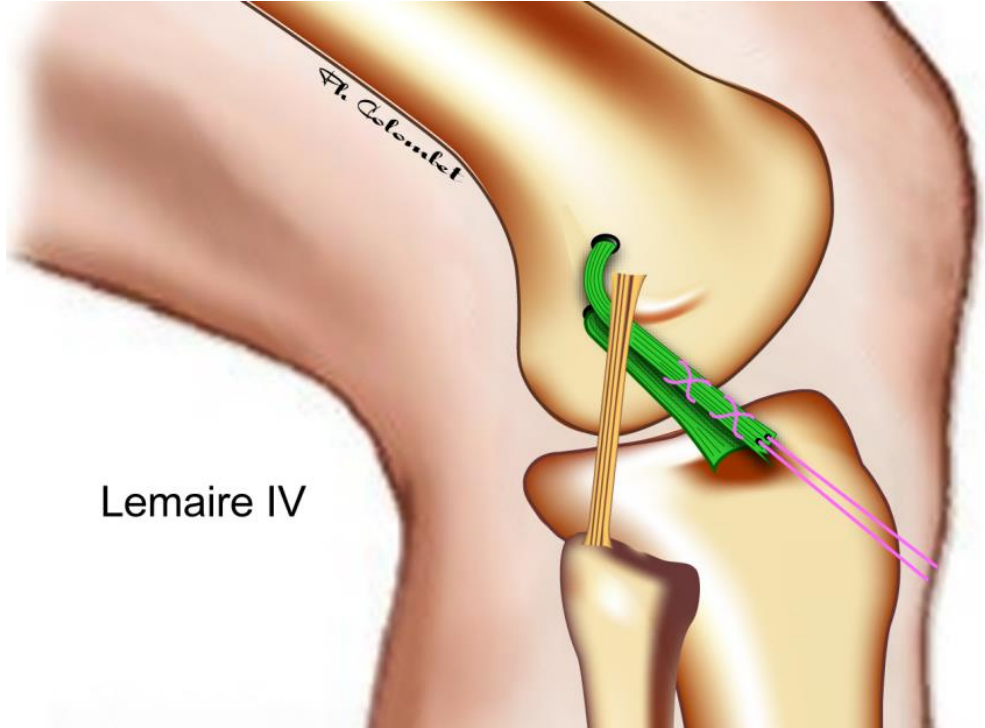
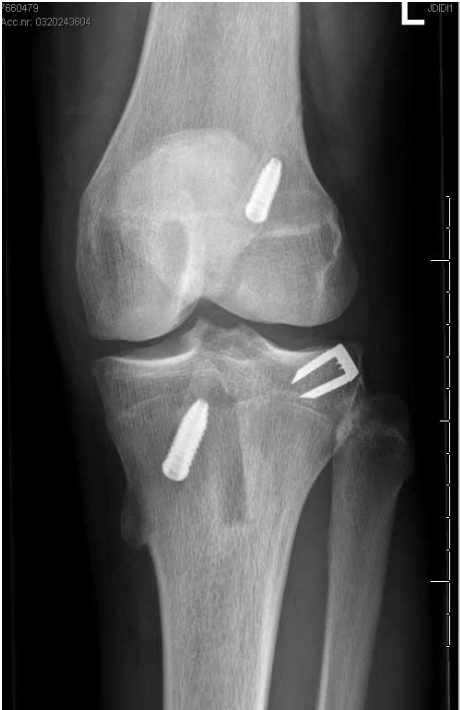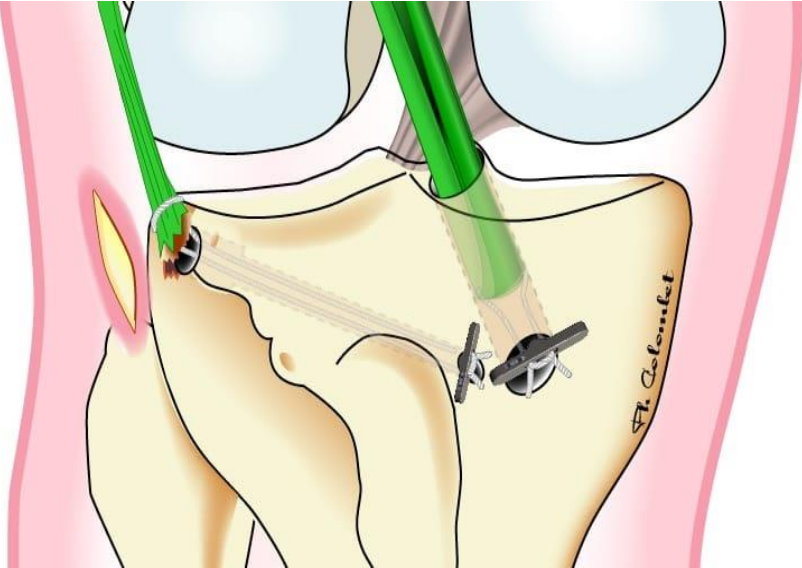Intraoperative guidance ACL + ALL



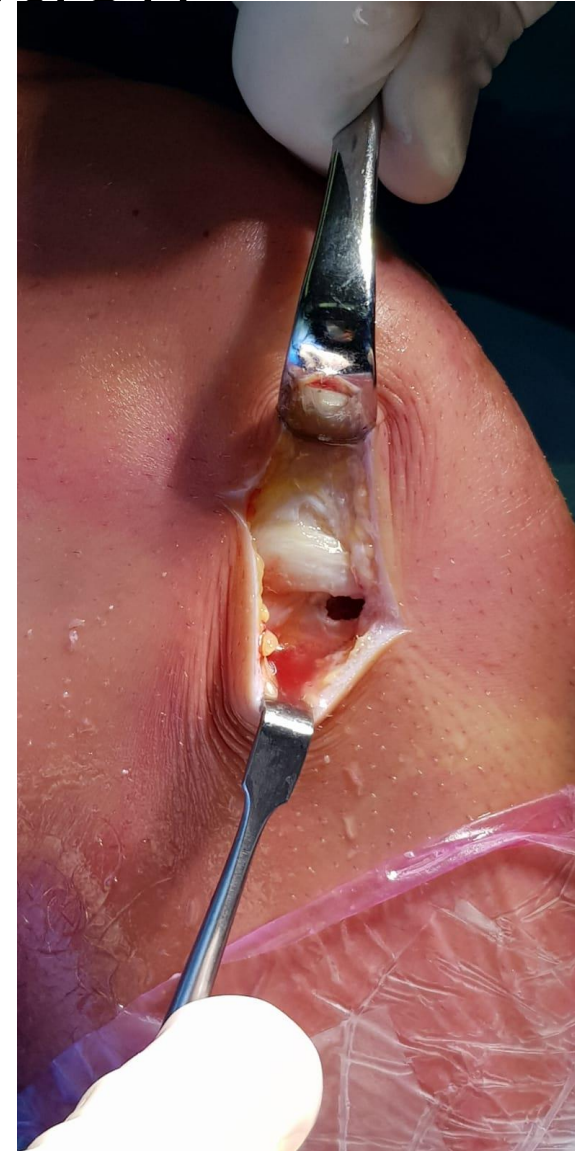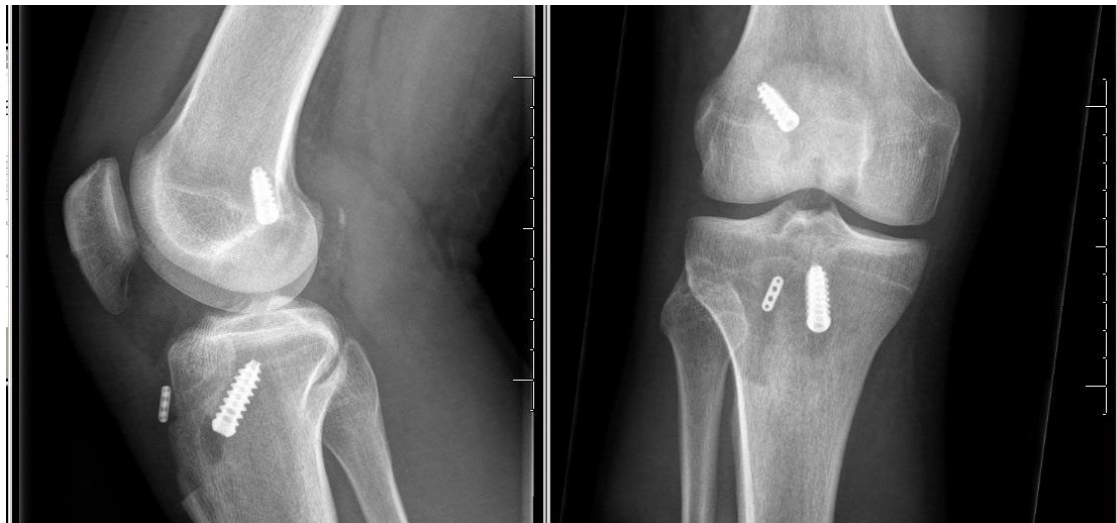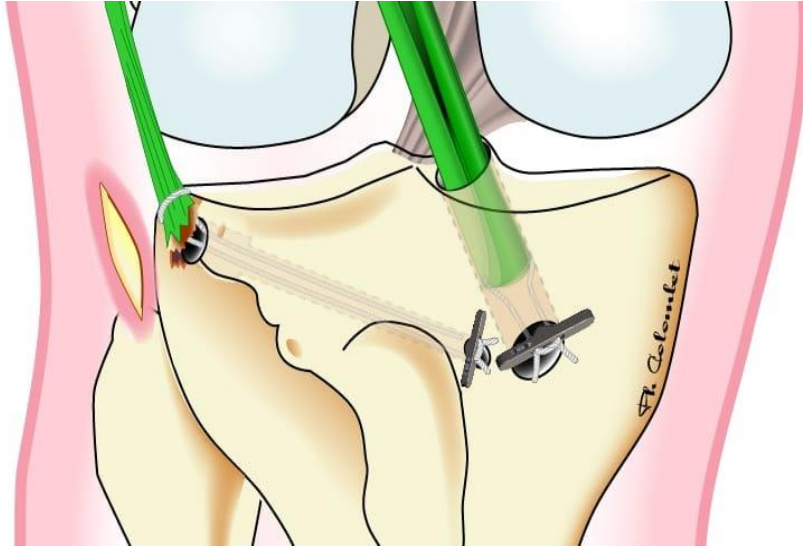
June 2018 > july 2019



Refixing Segond or reconstruction AL tenodesis?



Pull up / in technique ALL refixation



Conclusion

- ALL complex lesions and Segond avulsion are not rare (30 + %)
- Improving diagnosis and treatment
 - Improved Imaging Ultrasound (vs MRI)
 - Segond avulsion is attached to ITB / ALL complex
 - Surgical treatment or neglect /reconstruction ?
 - Fixation method ? Staple versus tension rope ..

