

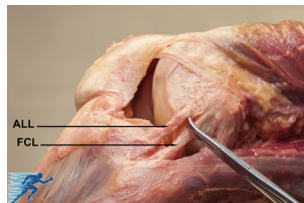
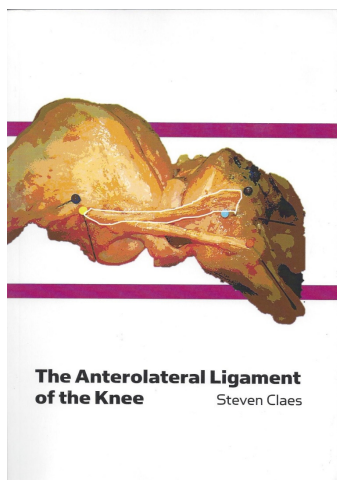


ALL ultrasound imaging Refixation Segond lesion

New concept in imaging and
approach to lateral avulsion fracture
/ Segond lesion .

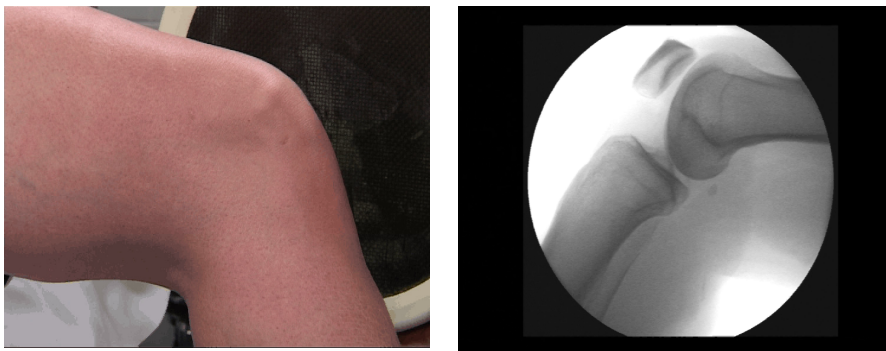
ICONE Orthopaedics & Sports Traumatology

ALL ligament ? November 2013 Belgium

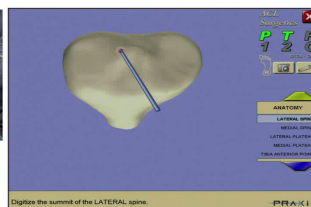
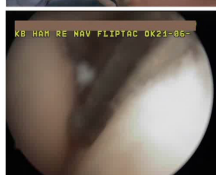
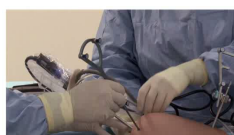
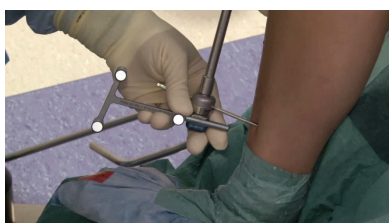ICONE Orthopaedics & Sports Traumatology


Fluoroscopic laxity AP




References frames / bone modelling



Laxity check



TEST 90° - DRAWER
REFERENCE POSITION



ACL
Surgeries
P T F
1 2 C

PRE-OP. LAXITIES


- DRAWER
- ROTATION 90°
- LACHMAN
- ROTATION 30°
- VAR-VALG. STABILITY
- PIVOT-SHIFT
- PRE-OP. SUMMARY

FLEXION: 89° ROTATION: 15° INT


Place the leg in the reference position for the drawer test (90°), without any drawer.

PRAXIM

Rotation



TEST 90° - ROTATION
ACQUISITION



Lateral (mm)

Ant 0 4 Post 4

Ext 13 13

13

Medial (mm)

Ant 2 2 Post 0 2

Axial rotation (°)

5 POSITIONS (MIN 10 - MAX 500)
FLEXION: 82° ROTATION: 10° EXT

Perform the rotation test at 90°.
BLUE pedal to stop the acquisition.

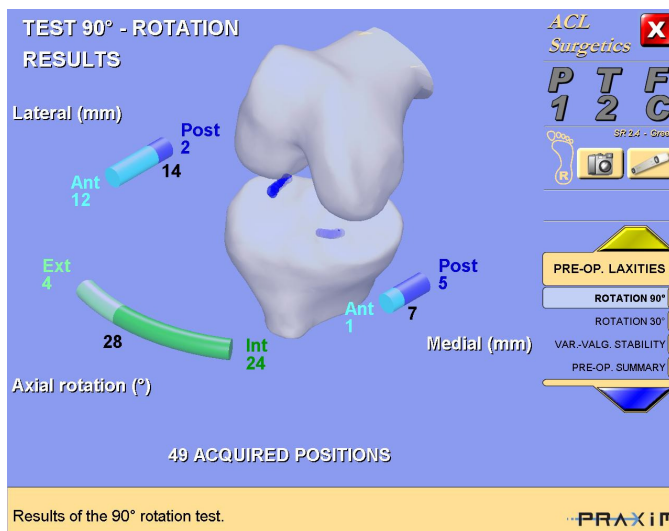
ACL
Surgeries
P T F
1 2 C

PRE-OP. LAXITIES

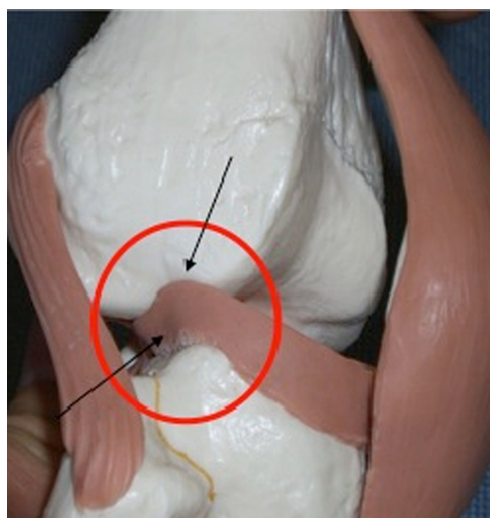
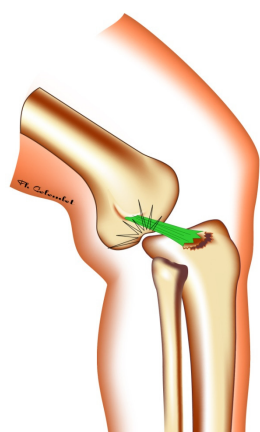
- DRAWER
- ROTATION 90°
- LACHMAN
- ROTATION 30°
- VAR-VALG. STABILITY
- PIVOT-SHIFT
- PRE-OP. SUMMARY

PRAXIM

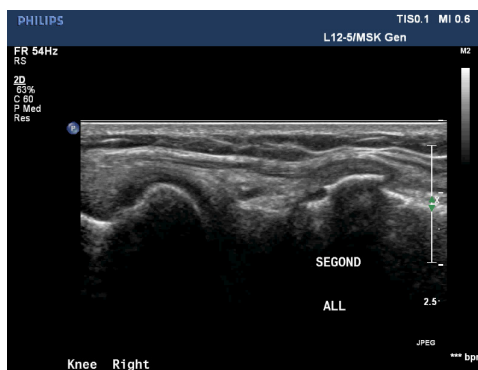
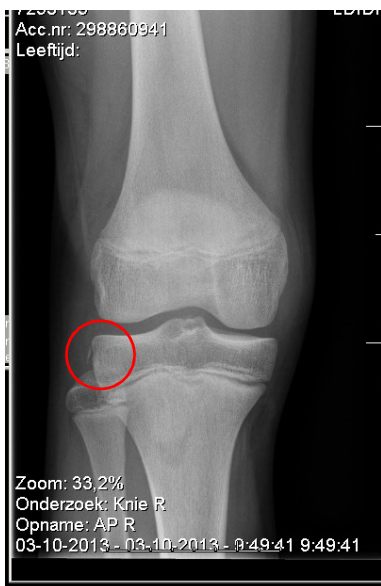
ALL instability ?



Combined lesions.

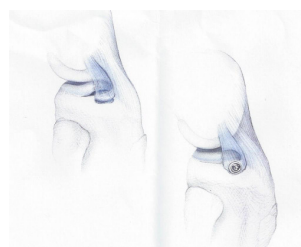


Segond fractuur

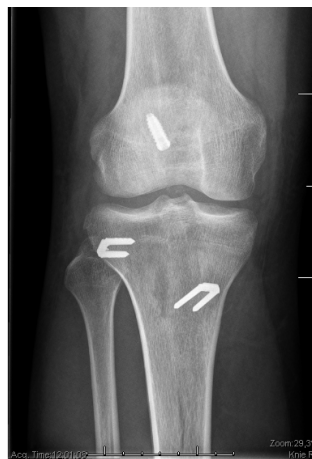
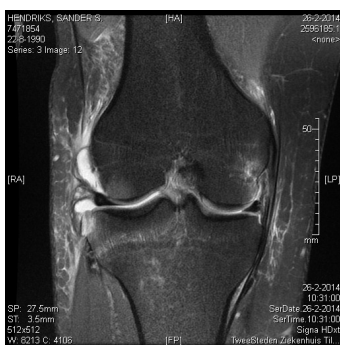
Imaging Segond avulsion

- Incidence in MRI 3 % Resnick USA
- Incidence in X ray CORR Hess D 9 %
- Incidence ultrasound 33 % (ICONE)
- Higher velocity trauma ?
- Refixation / Feagin :



ALL relation with Segond # ?



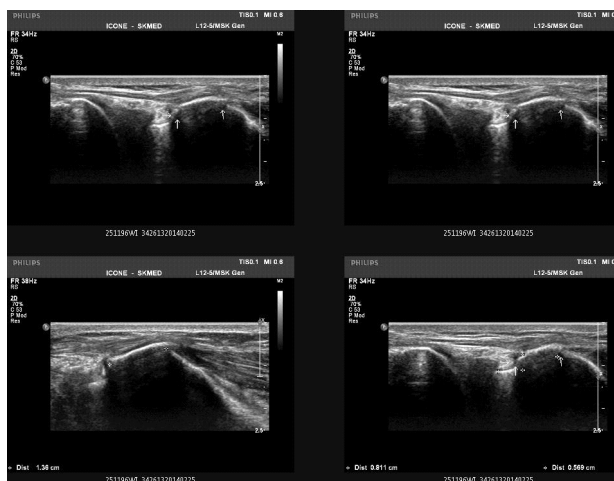
ICONE Orthopaedics & Sports Traumatology

Hypothesis

- Avulsion lesions are a possible goal for refixing important lateral structures.
- The same approach we have for lateral fibula and tibial spine avulsion fractures

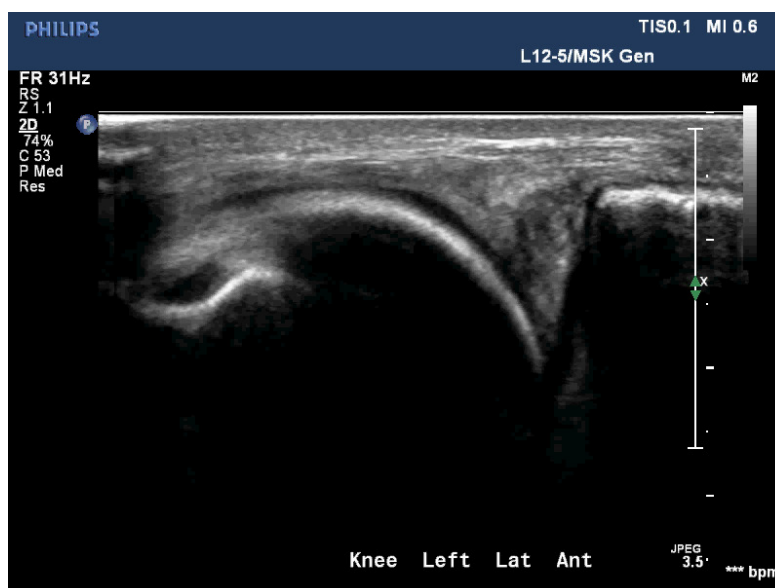
ICONE Orthopaedics & Sports Traumatology

US static / dynamic

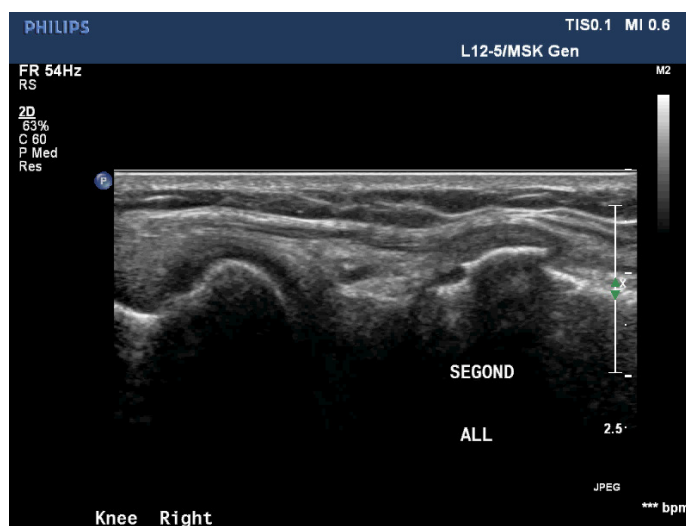

ICONE Orthopaedics & Sports Traumatology

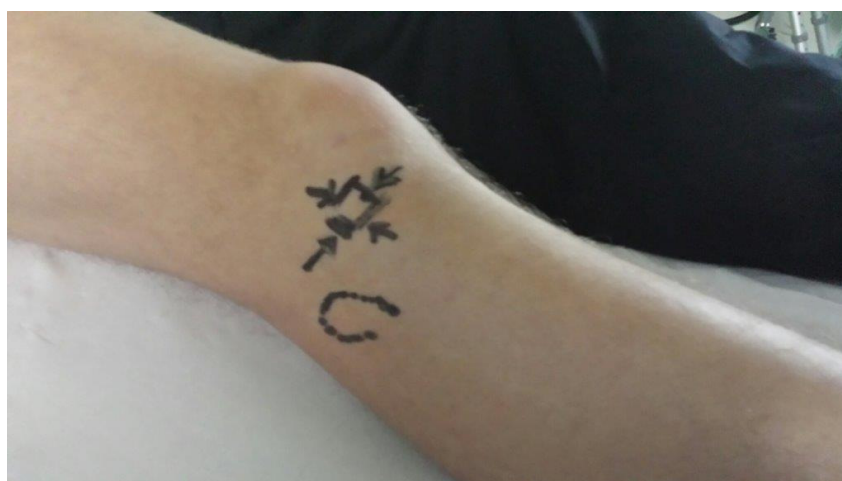Dynamic Imaging



US ALL ligament and



Preoperative marker of Segond avulsion / ultrasound



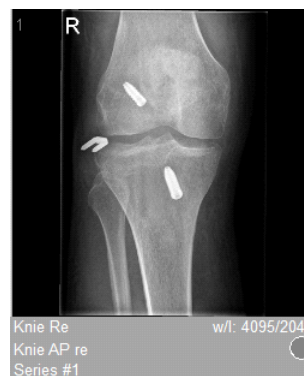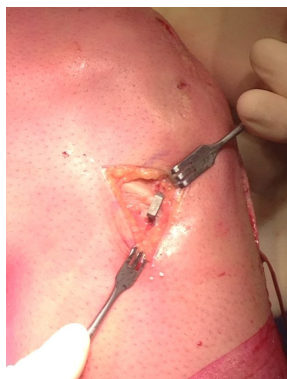ICONE Orthopaedics & Sports Traumatology

Peroperative imaging lift off lateral meniscus



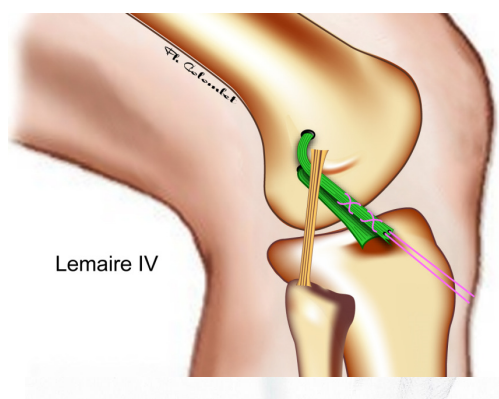
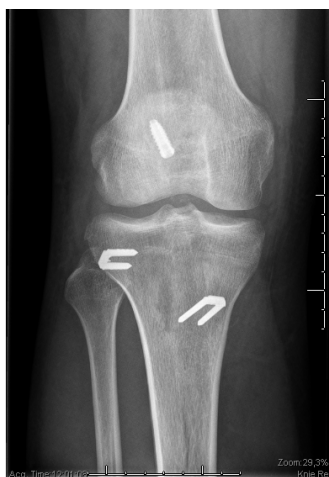ICONE Orthopaedics & Sports Traumatology

Case Report : Refixing ALL / second #
Checking the pivot on the table is pulling the staple off
/ prove of importance in stability ?



ICONE Orthopaedics & Sports Traumatology

Refixing Segond or reconstruction AL ?



ICONE Orthopaedics & Sports Traumatology

Conclusion

- We have new questions
 - Imaging
 - Indications
 - Surgical treatment
 - Some questions can be addressed by CAOS

ICONE Orthopaedics & Sports Traumatology

Future

- Improved imaging
- Improved intraoperative decision making
- A la Carte Surgery (generation 4)
- with CAOS

ICONE Orthopaedics & Sports Traumatology