



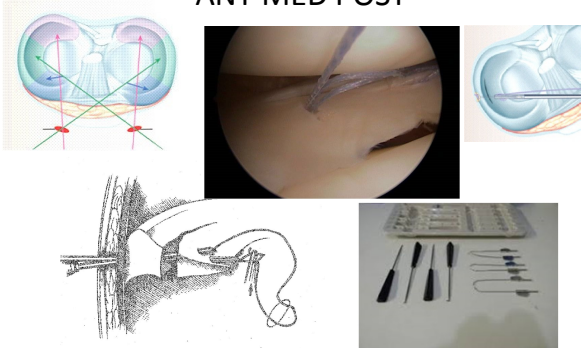
**Meniscus repair
Meniscus Ultrasound**

Burt Klos MD Ph D
Stephan Konijnenberg MD

Berlin 20. - 23. Oktober **DKOU 2015**


- ### Indications for repair
- Combined lesions ACL / Meniscus
 - Young , fresh
 - Lateral meniscus > medial meniscus
 - Hypermobile meniscus
 - Meniscus cysts ?

Meniscus zones ANT MED POST



The image contains several components: a top-left diagram of a knee joint with colored lines indicating the anterior, medial, and posterior zones of the meniscus; a top-middle photograph of an arthroscopic view of the knee; a top-right diagram of a knee joint; a bottom-left anatomical drawing of a knee joint; and a bottom-right photograph of various surgical instruments used in meniscus repair.

Meniscus ultrasound



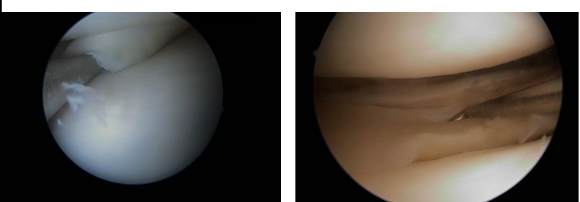
The image shows a clinical setting on the left with a patient lying on a table and a doctor performing an ultrasound. On the right is a close-up of the ultrasound screen, which displays a grayscale image of a knee joint. The screen includes technical details such as 'PHILIPS', 'T185.1 MI 0.9', 'L12-5MSK Gen', and 'Knee Left Lat Ant'.

European Meniscus Book 2016

- Chapter Meniscus Ultrasound
ICONÉ

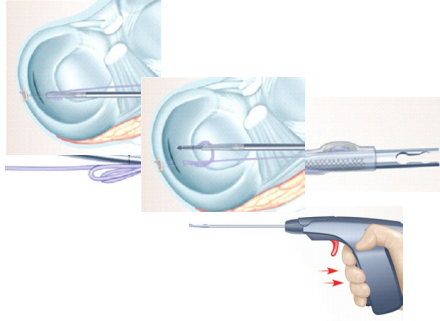
Video meniscus

Posterior horn rupture

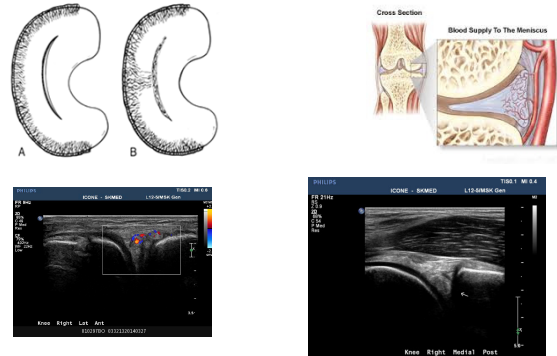


The image consists of two side-by-side arthroscopic photographs. The left photograph shows a normal view of the posterior horn of the meniscus. The right photograph shows a clear rupture or tear in the posterior horn of the meniscus.

All inside repair / POST



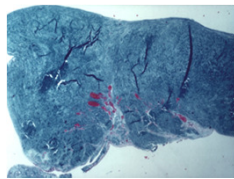
Vascular zones



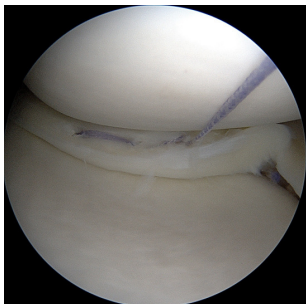
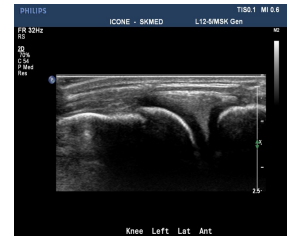
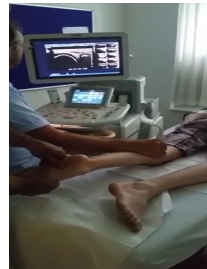Histology meniscus resection after repair

Neovascularisation

2 months	+++
5 months	++
5 months	+
12 months	+
20 months	0
48 months	0



Combined lesions



Video meniscus tear in ACL deficiency

Meniscus stable repair

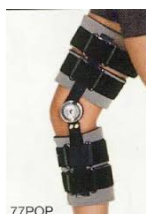- Video stable repair (ESSKA book)

Borderline

- Recurrent meniscus dislocation after repair
- Total dislocation lateral meniscus in 40 +
- Fresh meniscus in vascular zone in ACL reconstruction .

Postoperative care

- 4 wk brace , extension locked
- 1 wk day and night
- 2 wk crutches , part WB
- 8 dy anticoagulans



Conclusion

- Save the meniscus
- Try to repair more than you think
- Especially in young ACL injured with reconstruction
- Dynamic imaging

Faculty:
 J. Barth - France
 R. Becker - Germany
 F. Benazzo - Italy
 M. Bonnin - France
 M. Carmont - UK
 M. Clatworthy - New Zealand
 G. Felmet - Germany
 N. Gravelleau - France
 M. Hantes - Greece
 F. Kellberine - France
 B. Klop - Netherlands
 P. Landreau - Qatar
 J. Menetrey - Switzerland
 J.C. Monllau - Spain
 P. Neyret - France
 S. Parratte - France
 R. Seil - Luxembourg
 B. Sonnery Cottet - France
 P. Verdonk - Belgium
 A. Wilson - UK

Featuring with:
 J.N. Argenson - France
 O. Courage - France
 J.L. Prud'homme - France
 D. Washer - US