



6th Advanced Course on Knee Surgery

January 31st – February 5th, 2016 Val d'Isère - France

www.kneecourse.com

Tibial spine fracture

Burt Klos

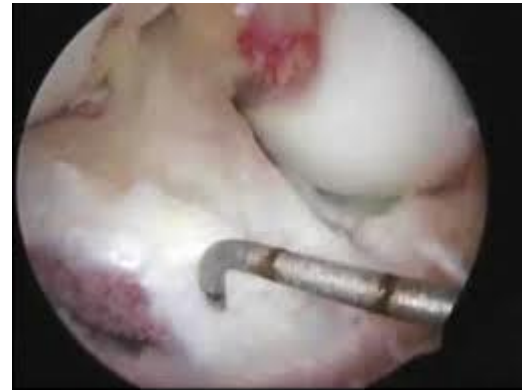ICONE

The Netherlands



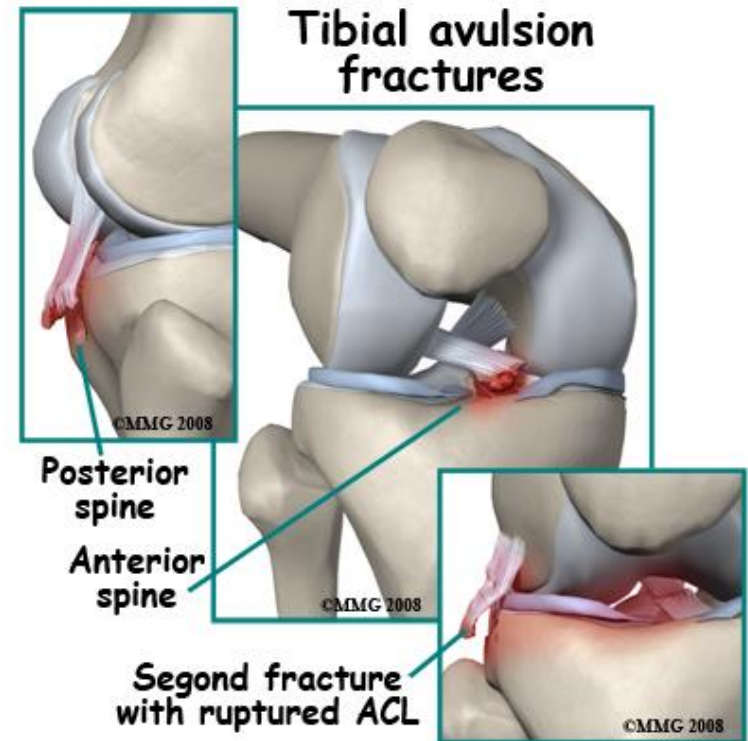
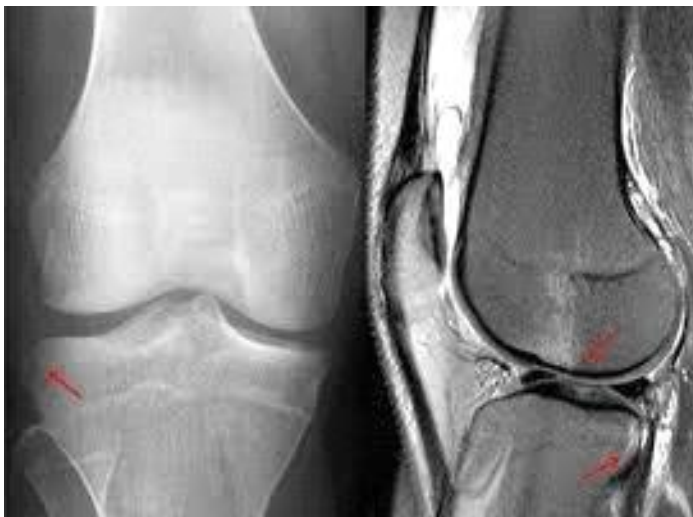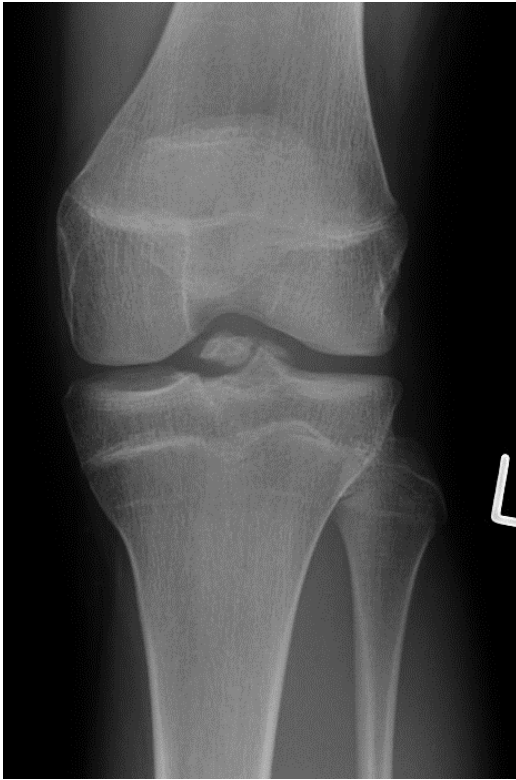Tibial spine fracture

- Adolescent
- Adult avulsion fracture



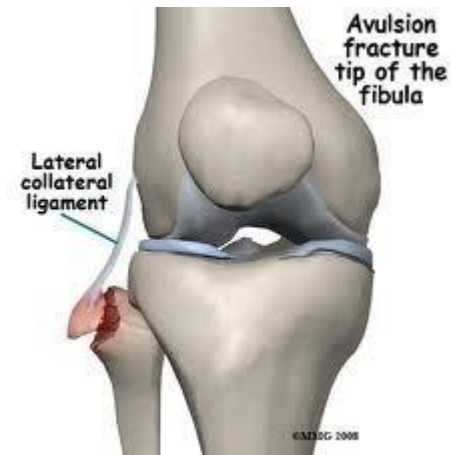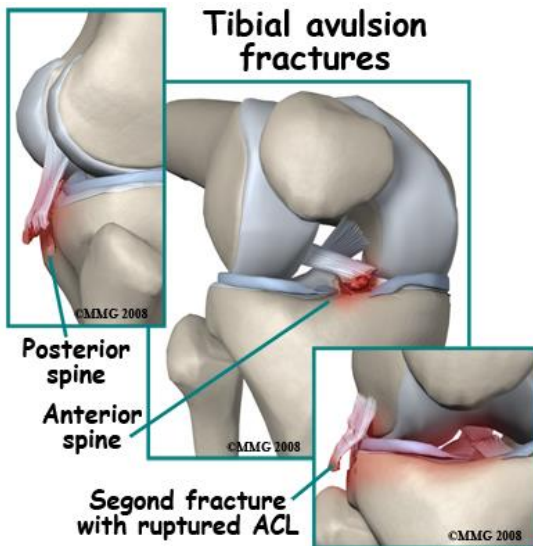
Bone lesions

- Second fracture
- Tibia plateau lateral posterior avulsion
- Impaction LFC



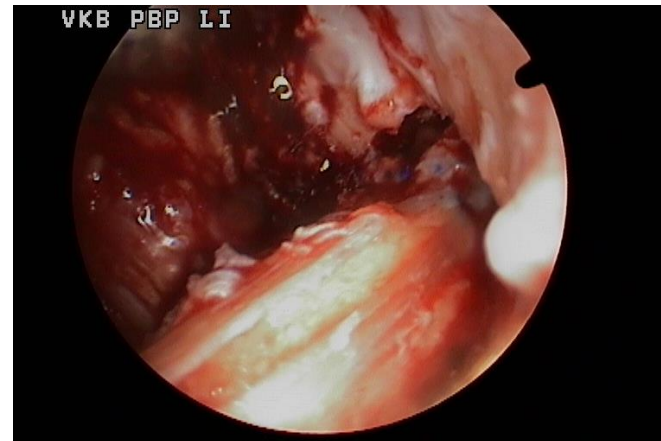
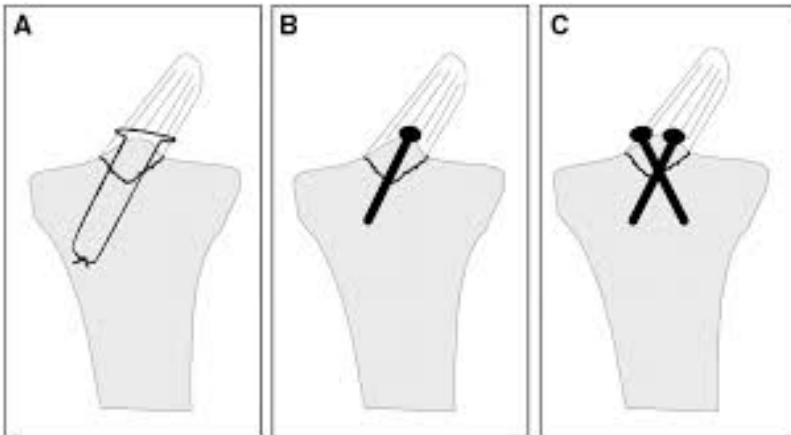
Hypothesis

- Avulsion lesions are a possible goal for refixing important lateral structures.

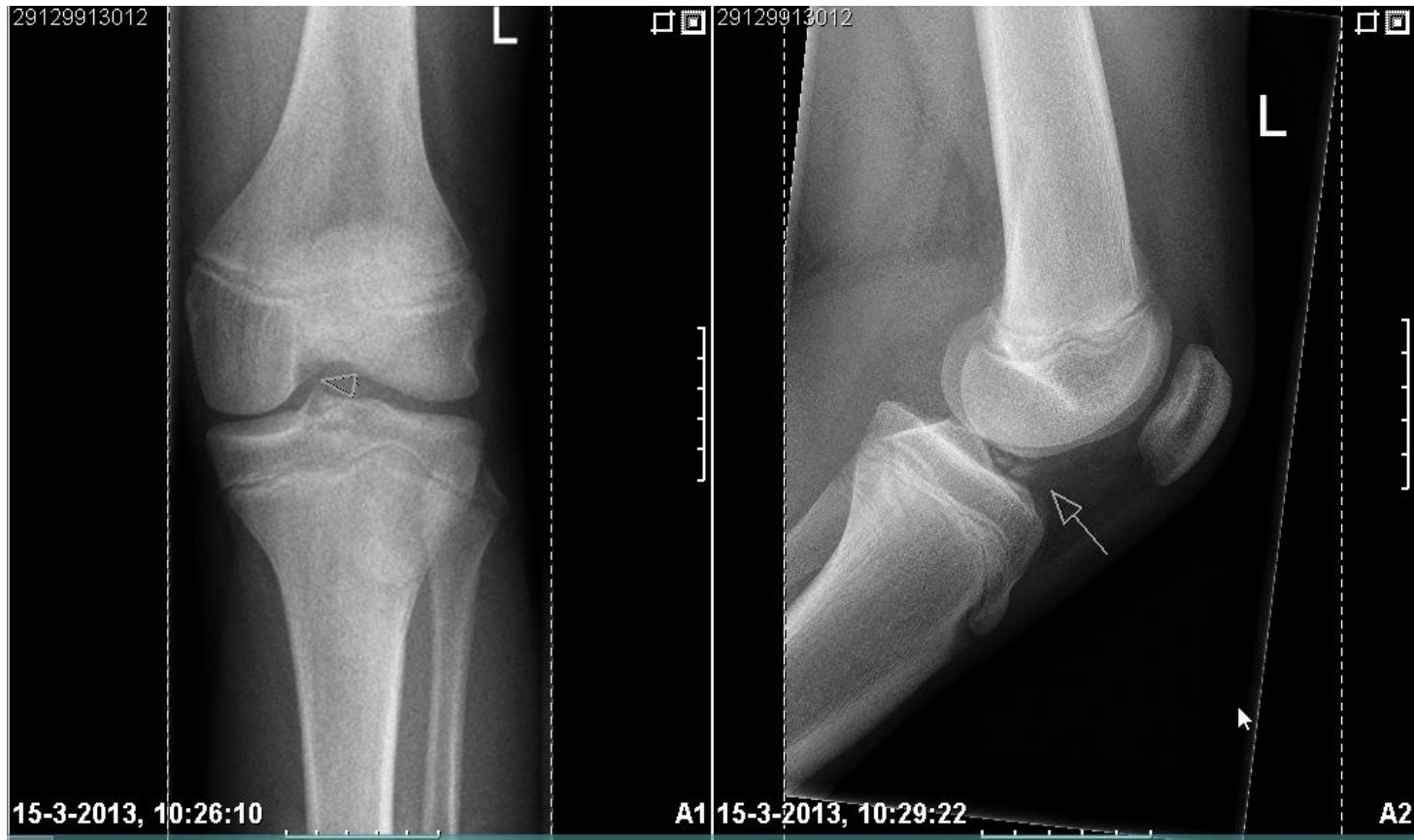

Arthroscopic treatment

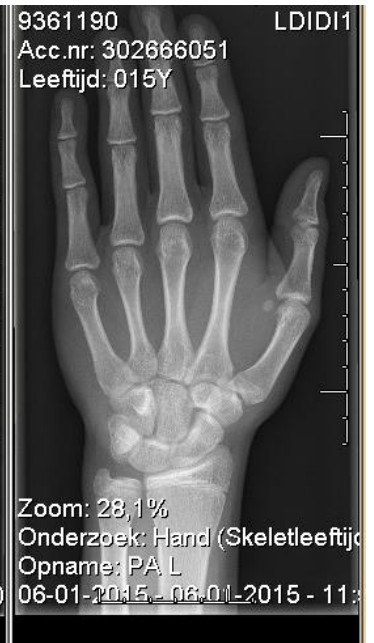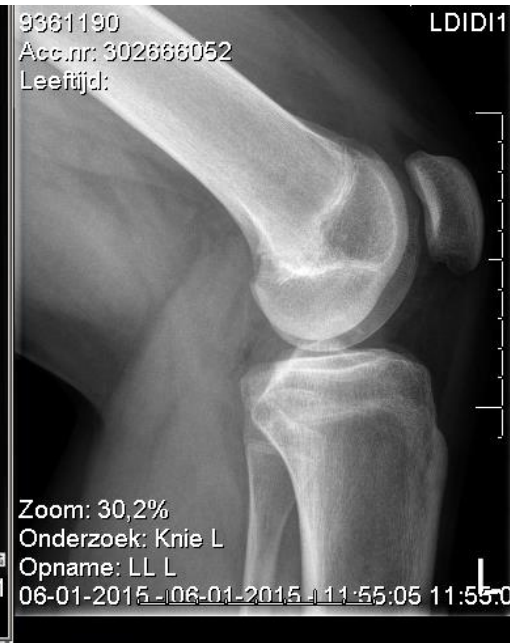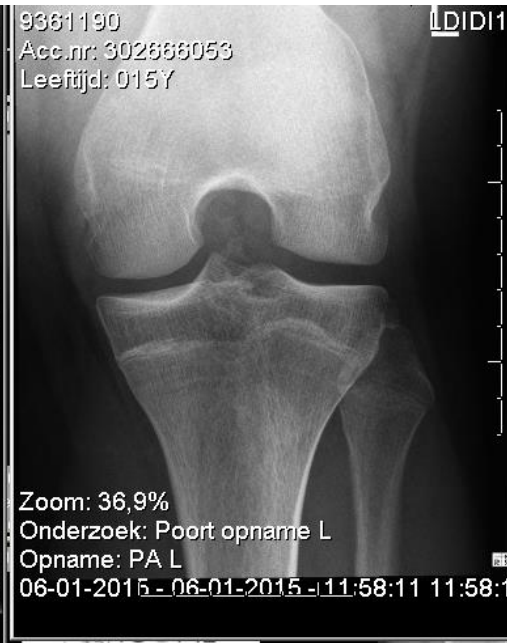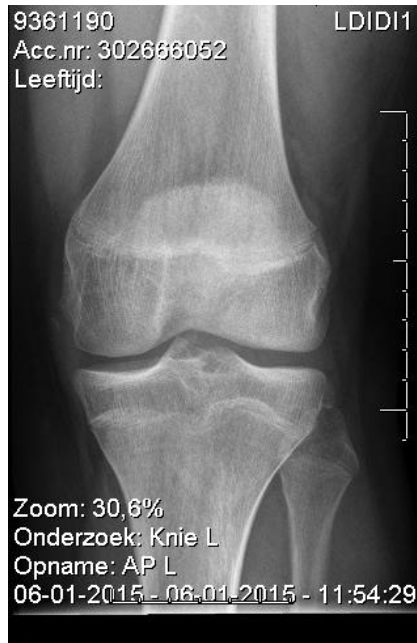clean out hematoma
Remove interposition
Deepening fracture / spoon
Plan B



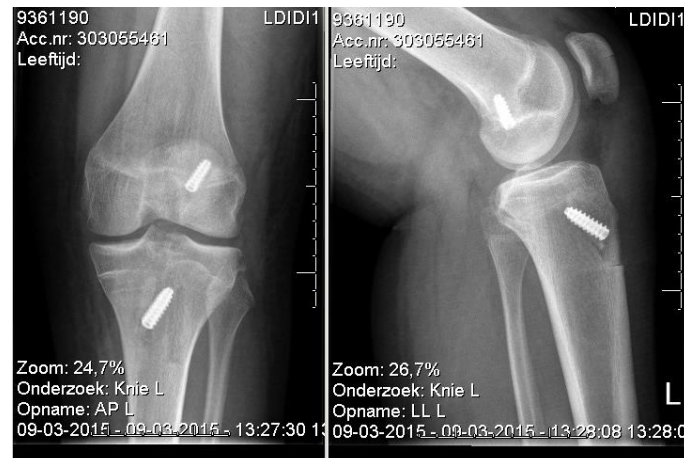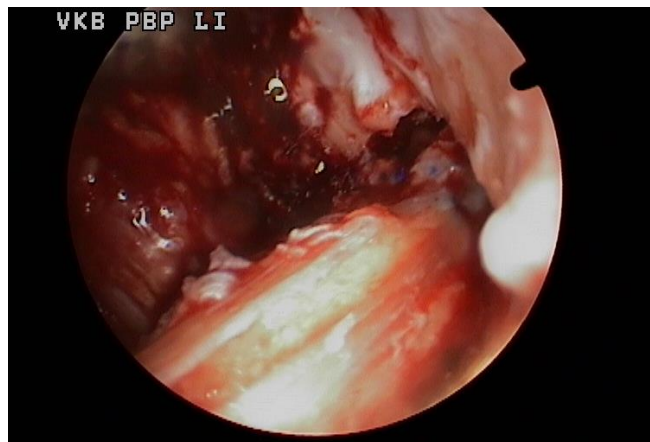
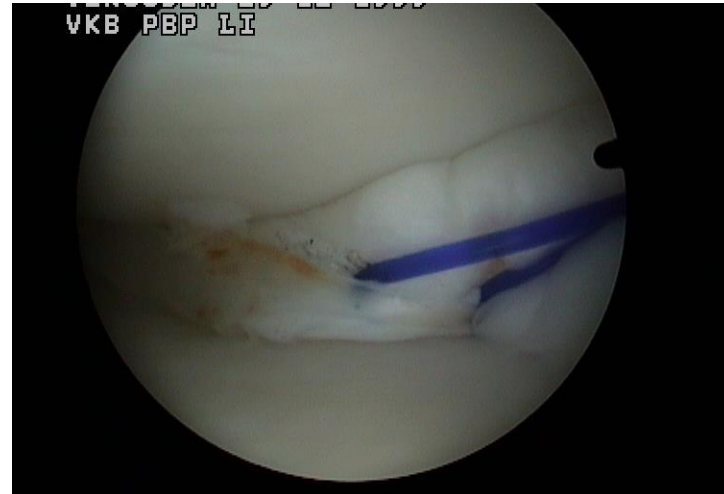
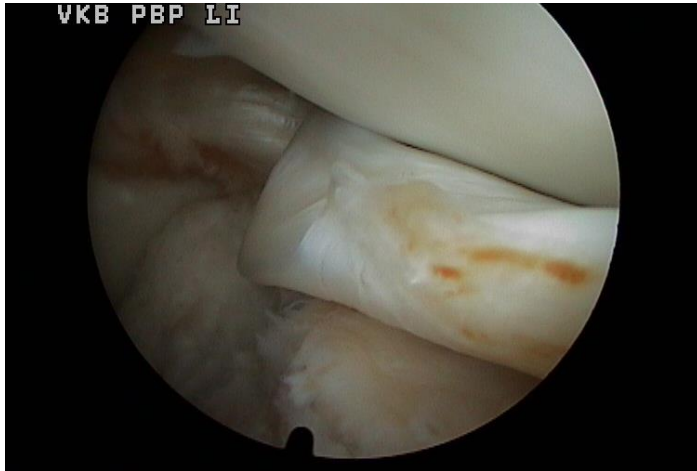
Male 14 yrs



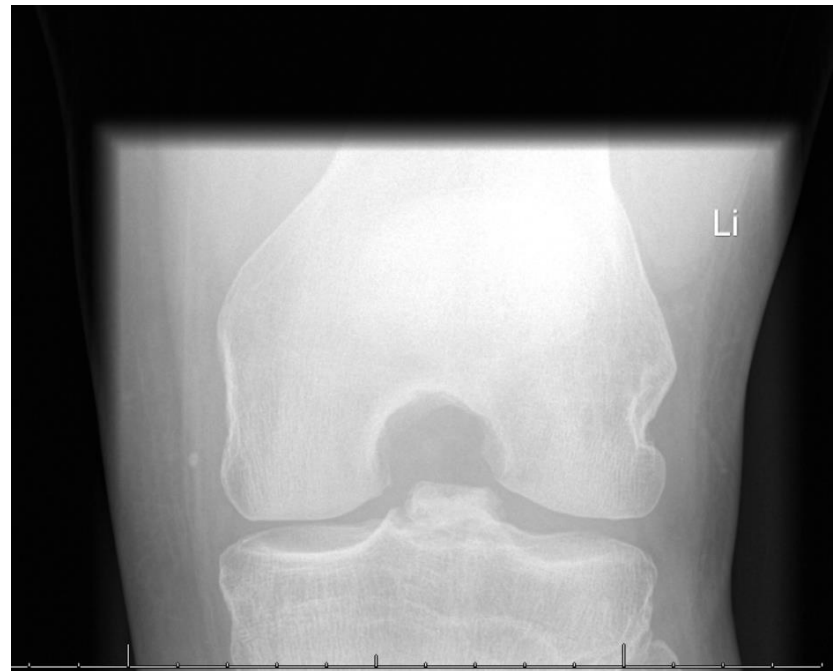
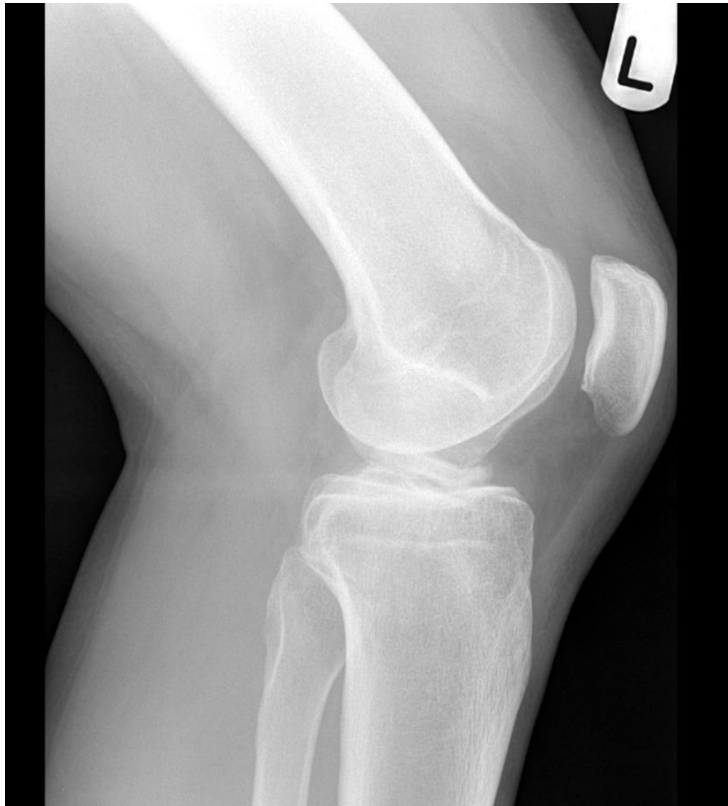1999 tibial spine



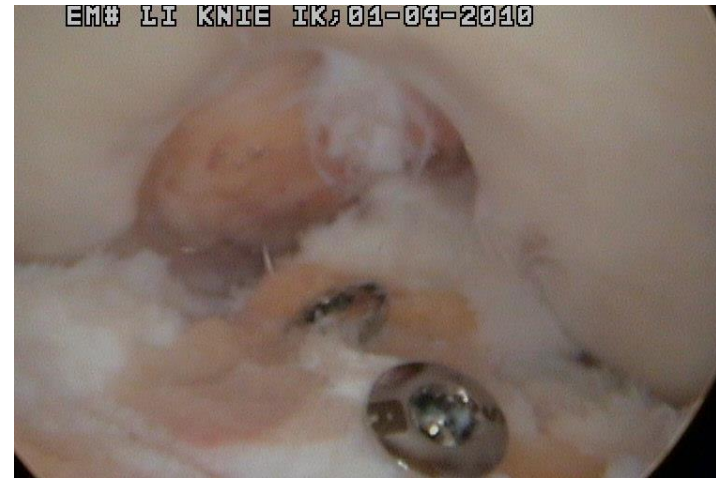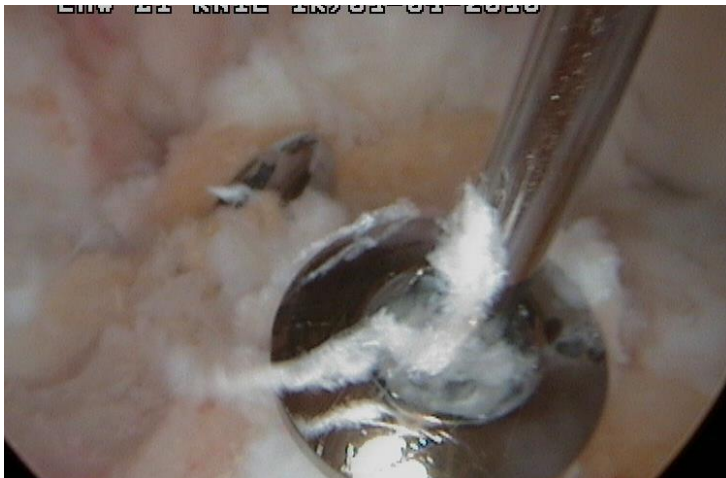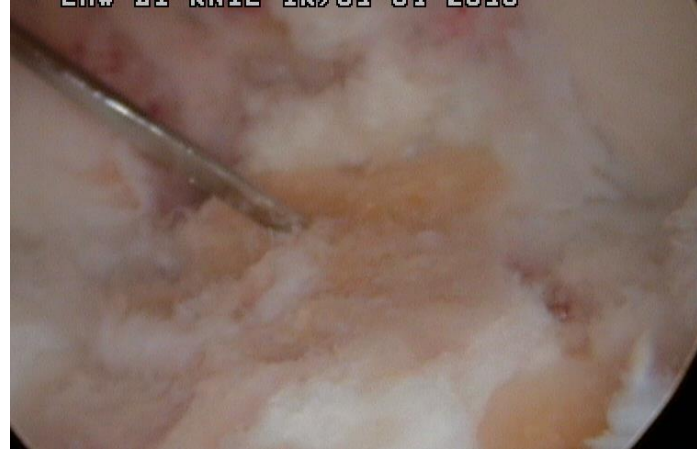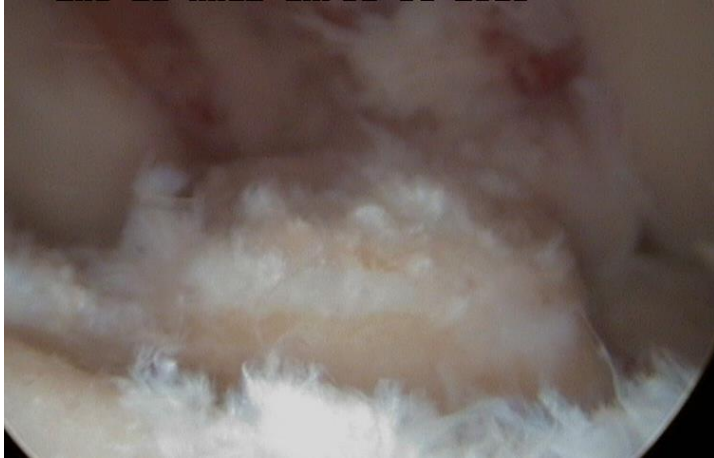
Meniscus dislocation



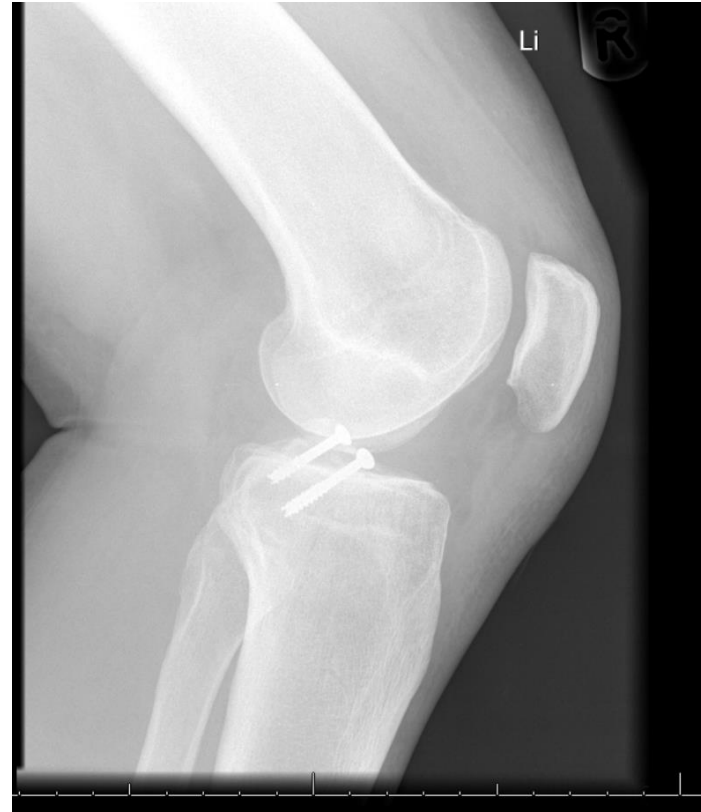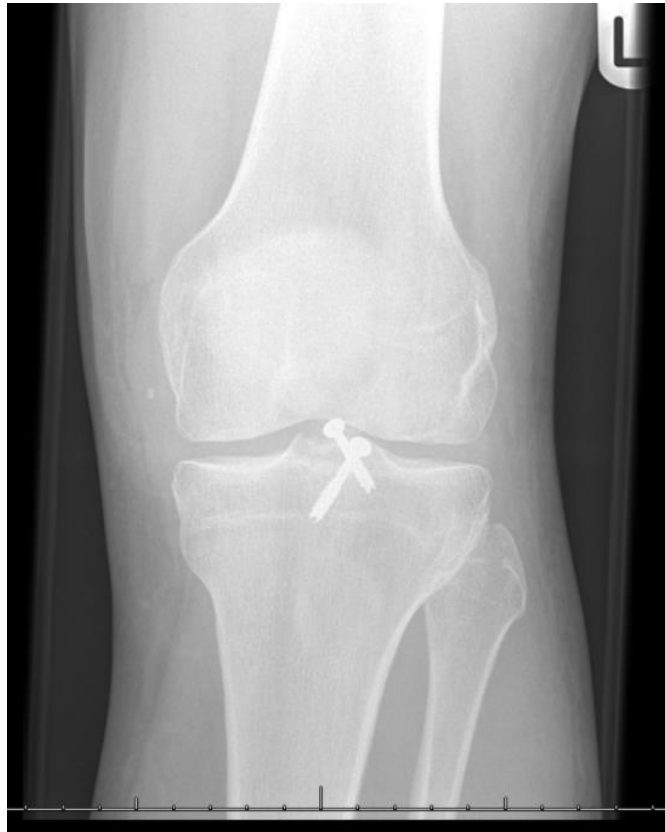Tibial spine



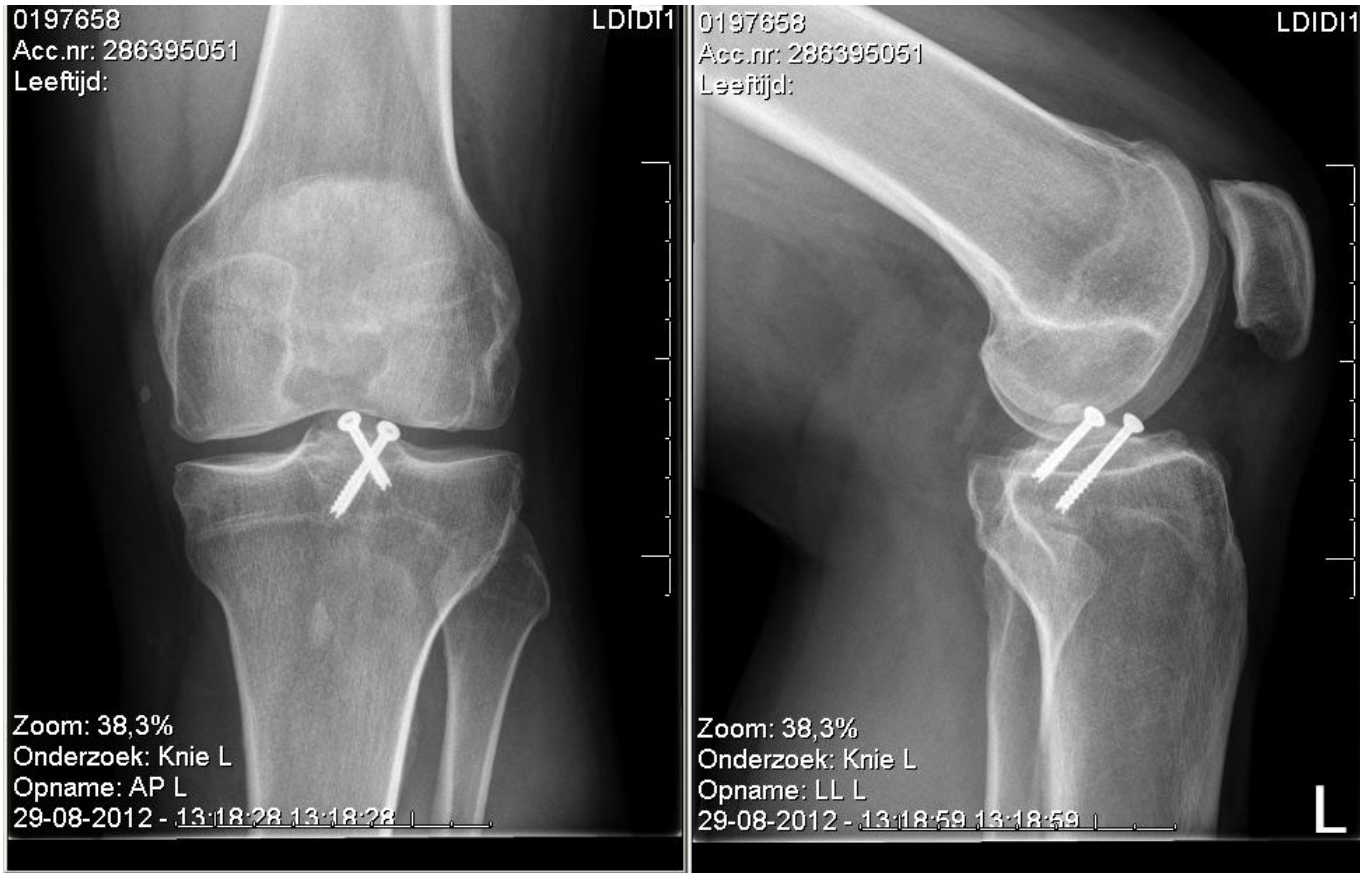Vd W intraoperative



Fluoroscopic fixation Open growth plate



Postoperative 2 yrs

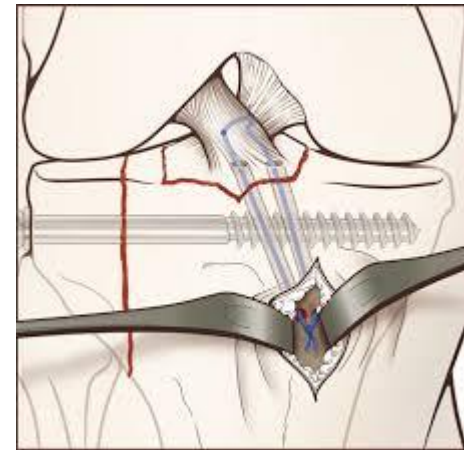
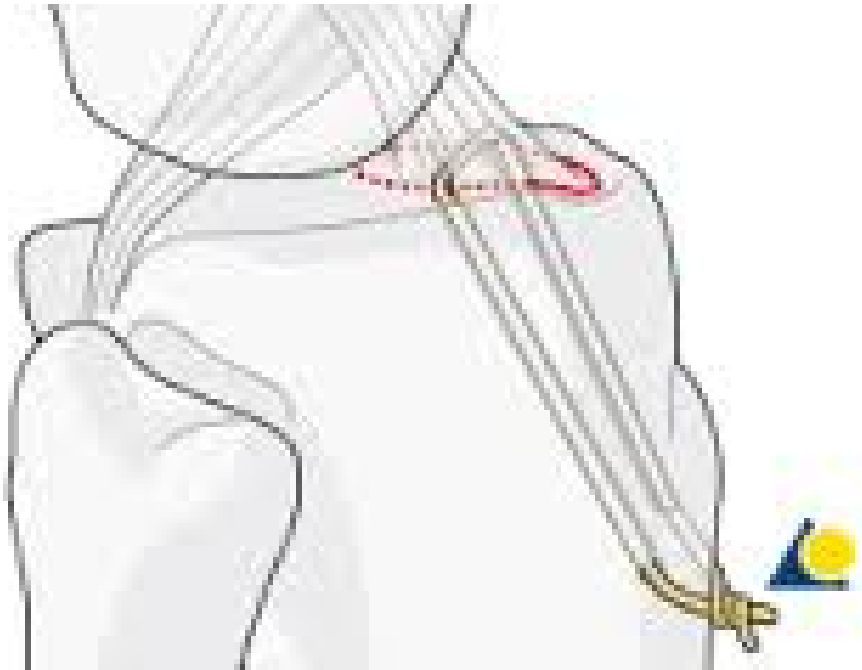

Suture fixation

drill guide

suture retriever

strong sutures or firewire



Suture technique

- Drilling K wire (2.4 mm with ACL guide)
- Over drill entry point (4.5)
- Entry K wire upside down with wire
- Suture retriever
- Second drilling (step 1-2)
- Loop wire pull through fiber wire outside .
- Suture over bone or suture disc .

Conclusion

- Adequate diagnosis with additional imaging
- Adequate decision making
- Adequate fixation / timing of surgery

