



6th Advanced Course on Knee Surgery

January 31st – February 5th, 2016 Val d'Isère - France

www.kneecourse.com

Extensor mechanism avulsions

Burt Klos

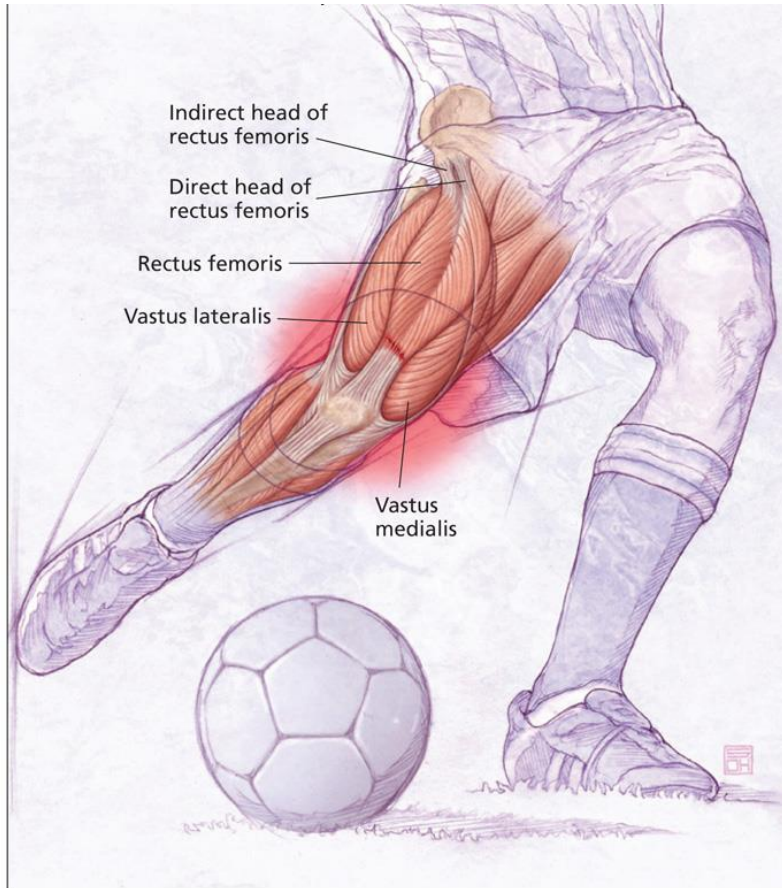
ICONE

The Netherlands

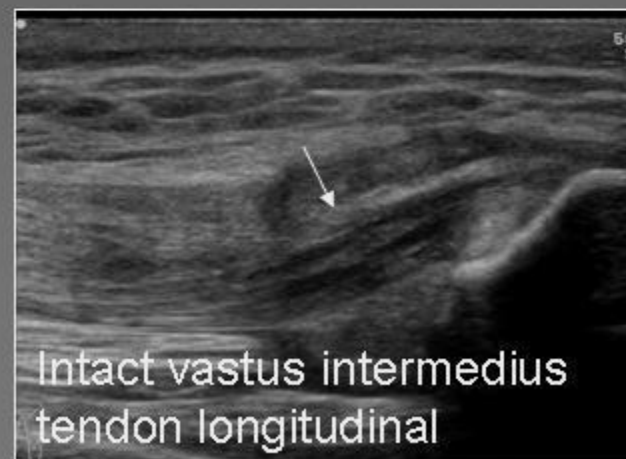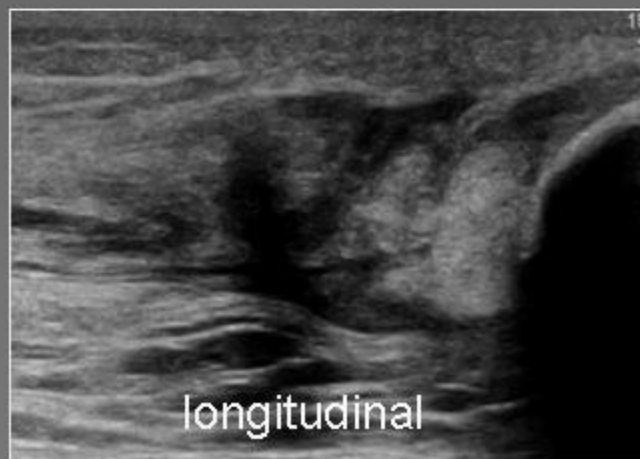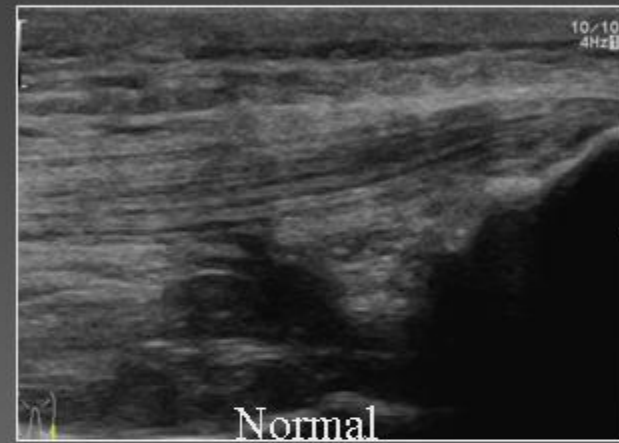
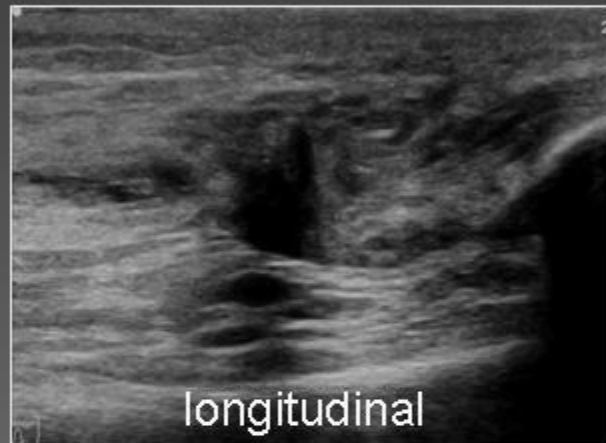
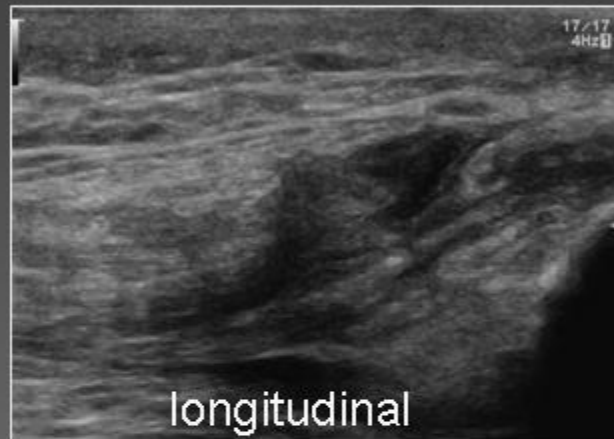


Quad tendon injury

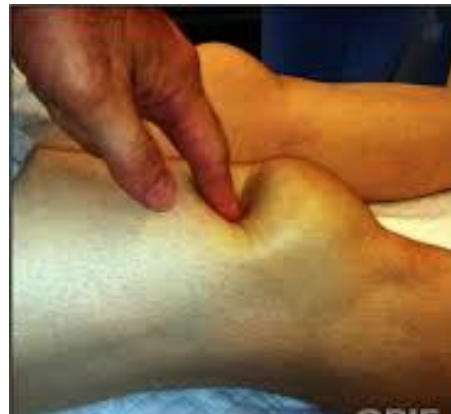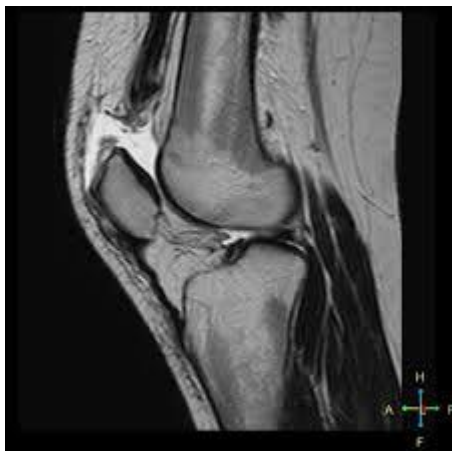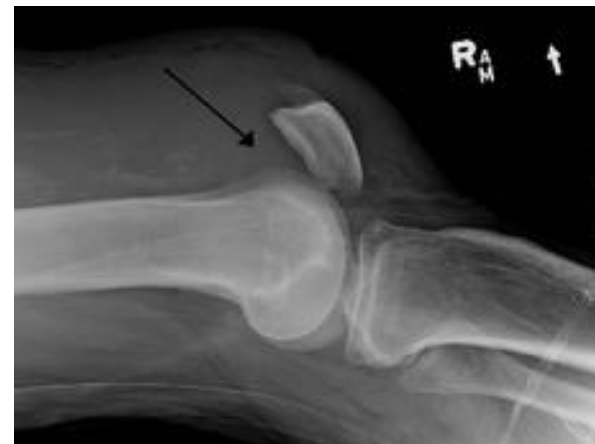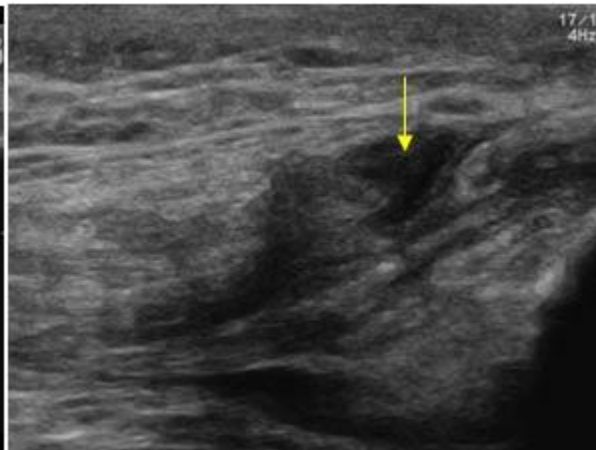
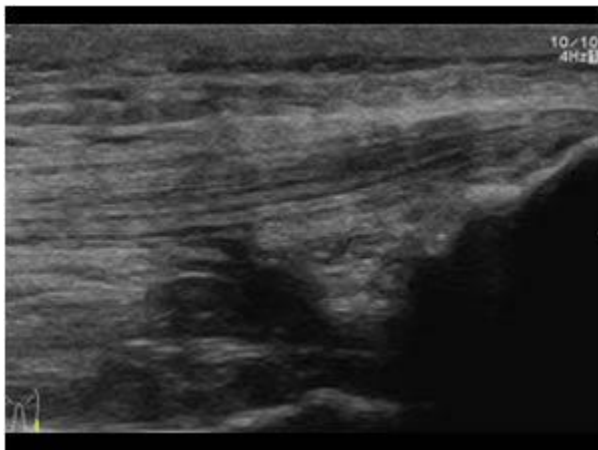
Patella tendon injury

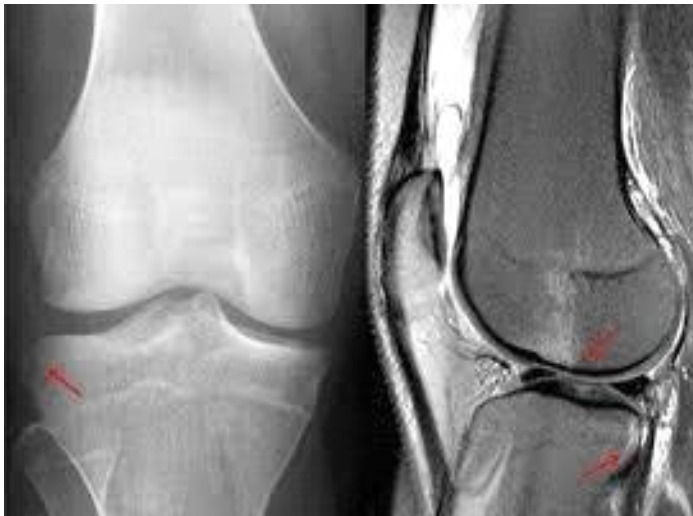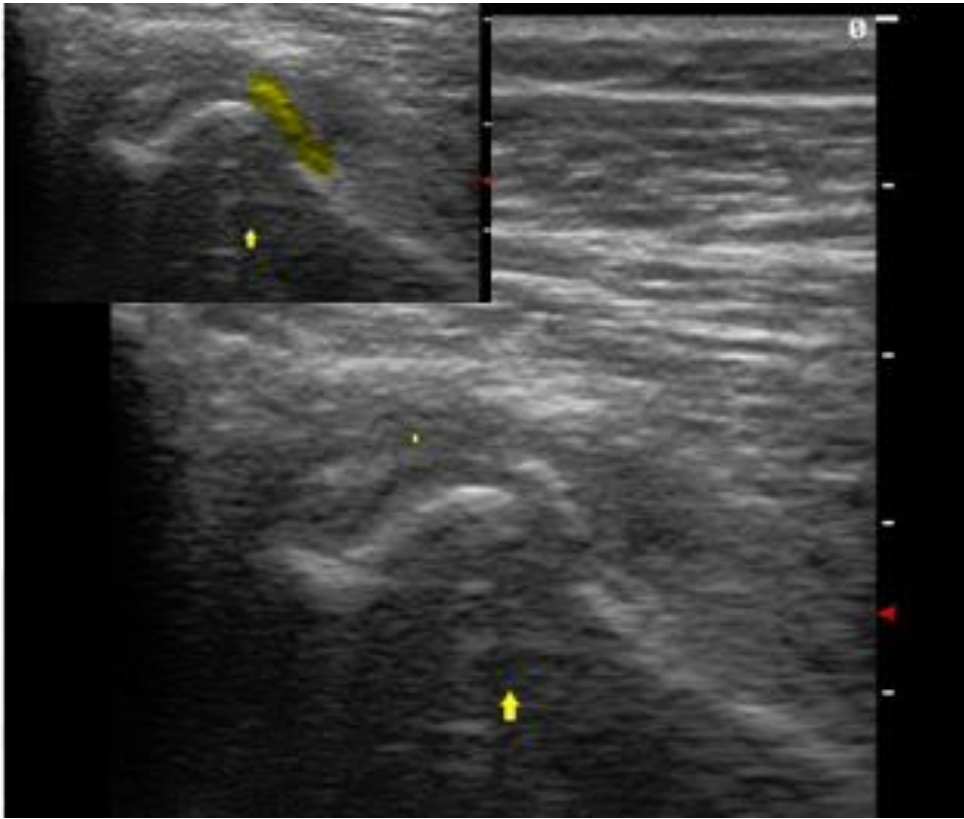


Quadriceps tendon rupture with a large defect in the rectus femoris tendon but intact vastus intermedius tendon



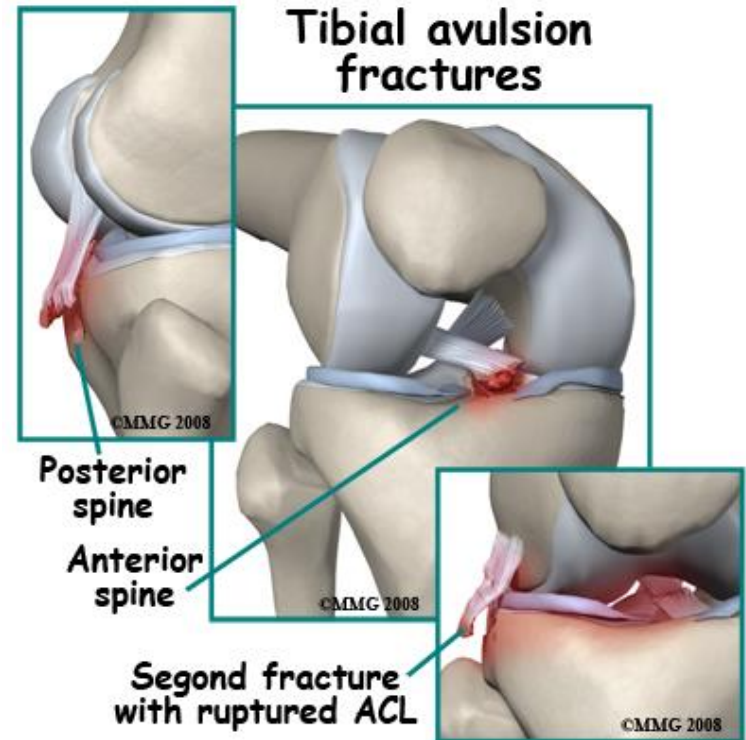
Quad tendon





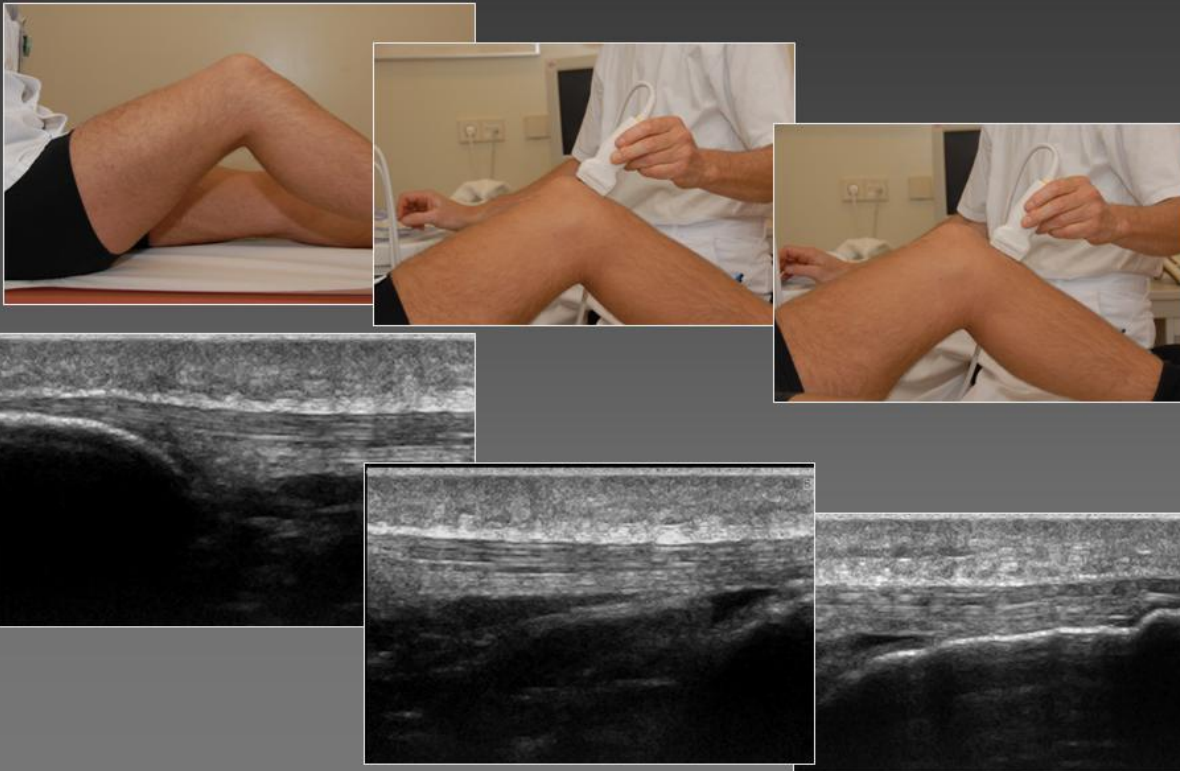
Bone lesions

- Segond fracture
- Tibia plateau lateral posterior avulsion
- Impaction LFC

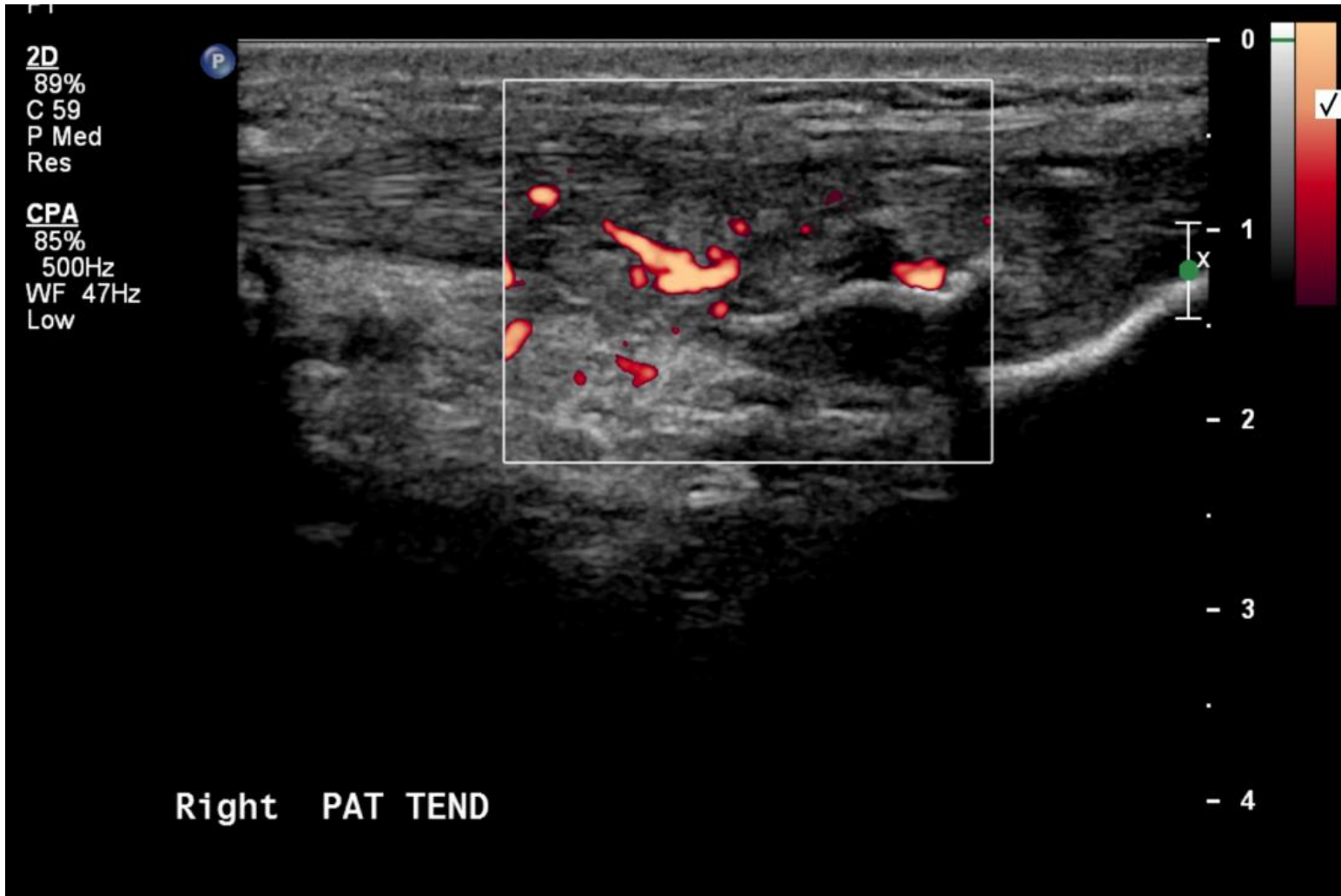


Patella tendon

Anterior knee: patellar tendon longitudinal

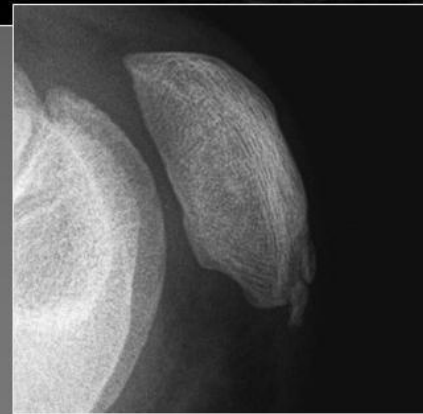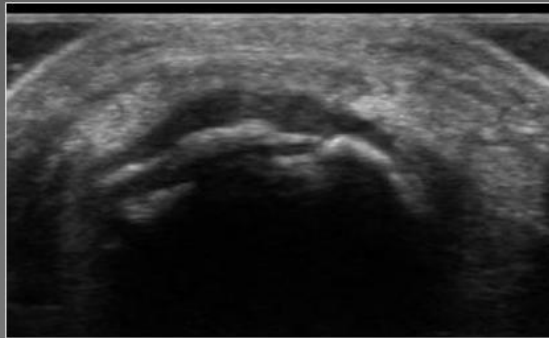
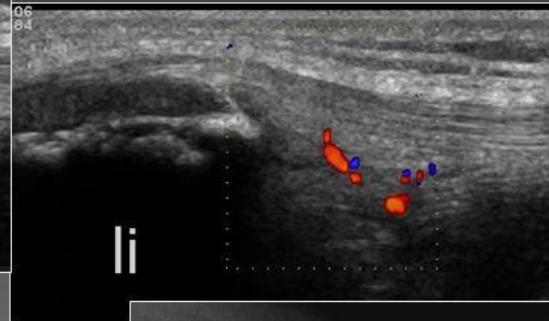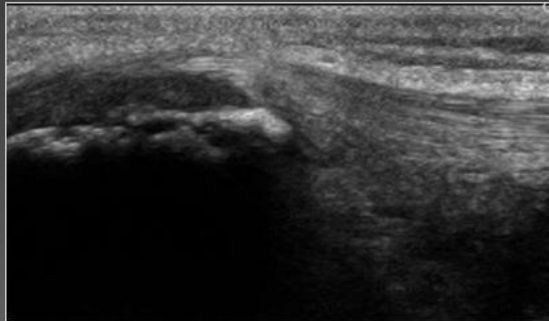


Doppler ultrasound inflammation

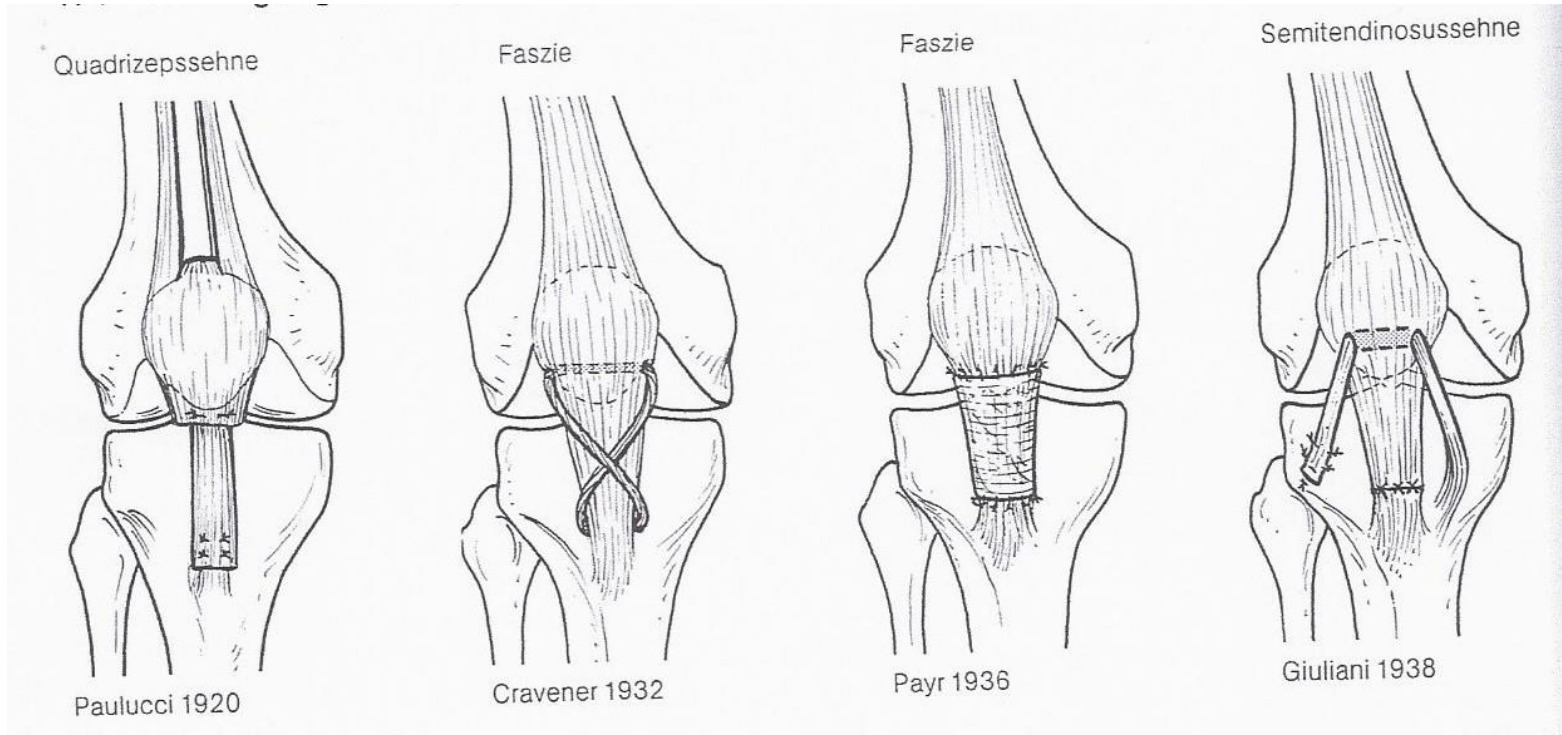


Patella tendon

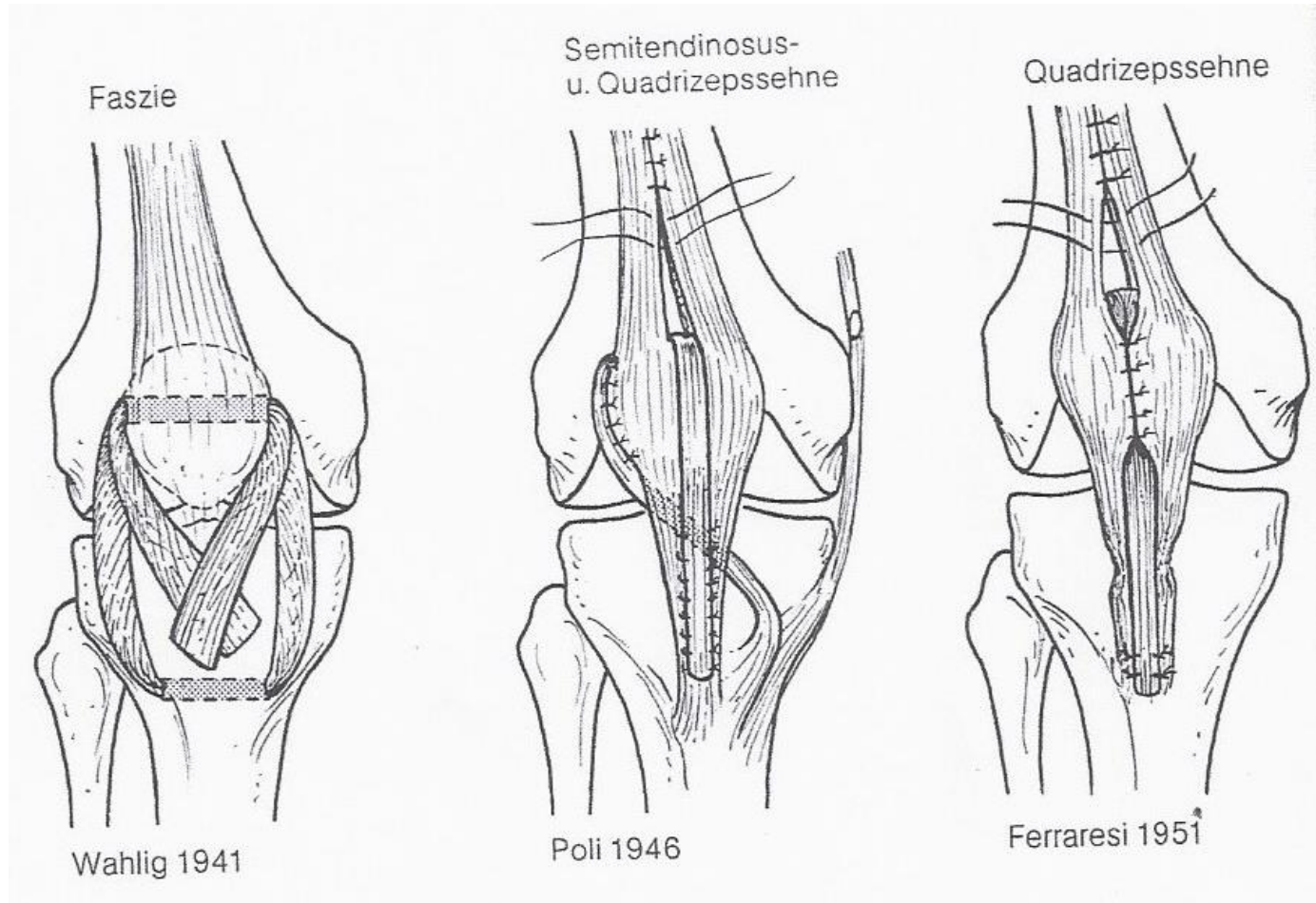
Sinding Larsen Johansson disease in
a 13 year old boy



Patella tendon reconstruction

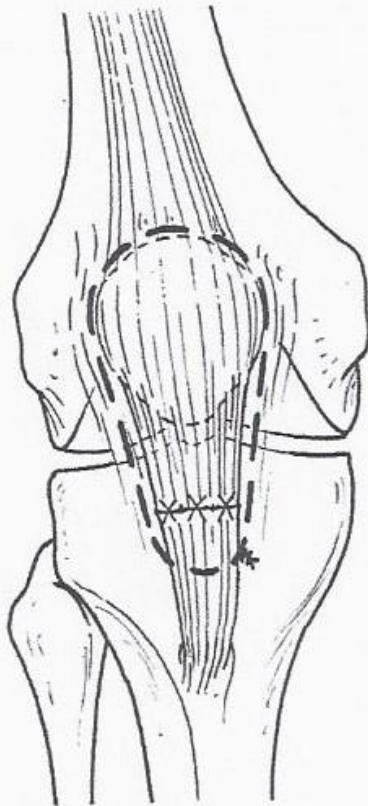


Patella tendon reconstruction



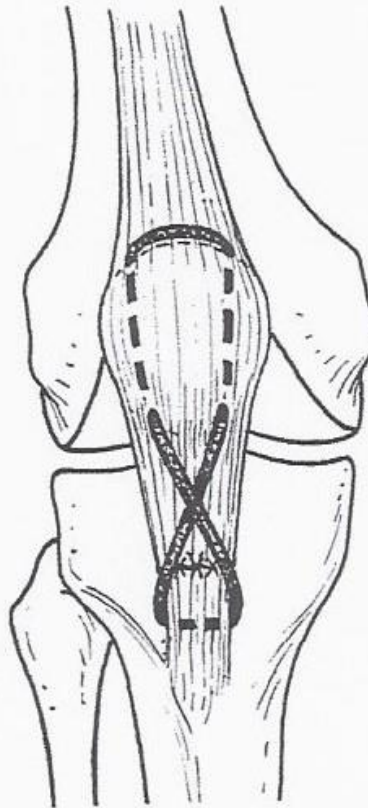
Patella tendon augmentation

Drahtschlinge



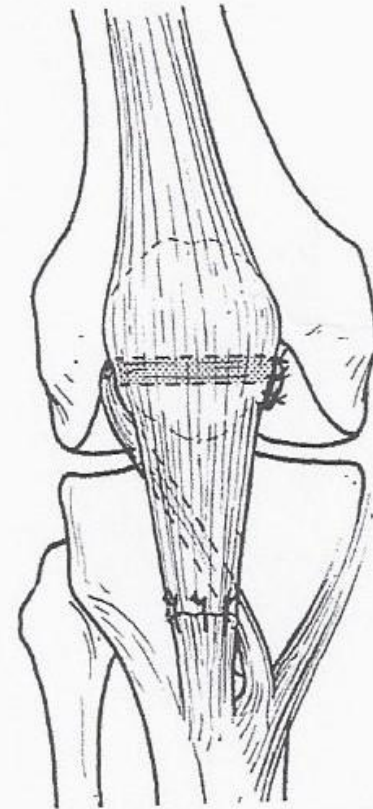
Mangini 1954

Cutis



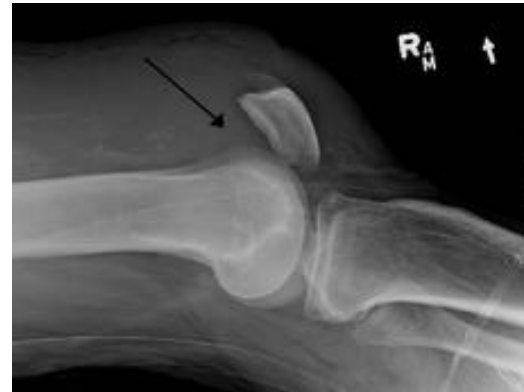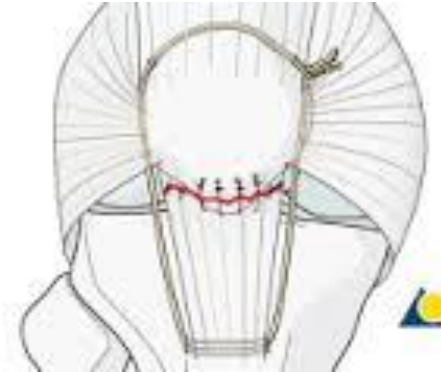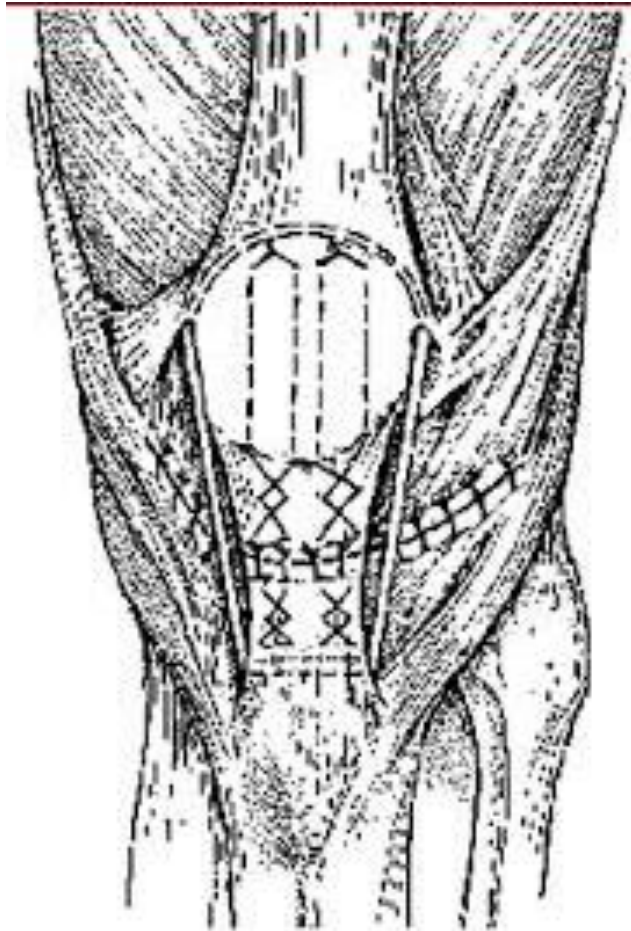
Belenger 1955, Judet 1960

Semitendinosussehne



Kelikian 1957

Patella tendon repair



Conclusion

- MRI and Dynamic ultrasound diagnosis
- Most lesions partial > conservative
- Operative treatment > many different techniques